

Case Report

An Incidental Aneurysm of the Interventricular Membranous Septum

Senol Yavuz MD¹, Cuneyt Eris MD¹, Tugrul Goncu MD¹, Mustafa Sezen MD¹, Yusuf Ata MD¹, Tamer Turk MD¹

Abstract:

Aneurysm of the interventricular membranous septum is a very rare cardiac anomaly in the absence of ventricular septal defect. We report the case of a 22-year-old man with aneurysm of the interventricular membranous septum incidentally determined during aortic valve surgery. The patient underwent successful aortic valve replacement and aneurysm repair.

Patients with the aneurysm of the interventricular membranous septum who are asymptomatic must be followed closely in terms of potential cardiac complications.

Keywords: aneurysm, aortic valve replacement, interventricular membranous septum

Introduction

Aneurysm of the interventricular membranous septum (IVMS) is a very rare cardiac anomaly which occurs in 0.3% of patients with congenital heart disease and in up to 19% with ventricular septal defect.¹ The exact anatomic basis for such an aneurysm shows diversity. Aneurysm of the IVMS may develop idiopathically or as a consequence of spontaneous closure of a ventricular septal defect. Herein, we report a case with aneurysm of the IVMS incidentally determined during aortic valve surgery.

Case Report

A 22-year-old man was admitted to Bursa Yüksek İhtisas Education and Research Hospital, Bursa, Turkey, because of very poor exercise tolerance, palpitation, and dyspnea of six months duration. Echocardiography demonstrated severe calcific aortic valve stenosis, moderate aortic valve insufficiency, mild dilated aorta, and left ventricular hypertrophy.

The patient underwent surgery. The ascending

aorta was dilated mildly and opened in an oblique fashion with an incision carried down into the non-coronary sinus. The aortic valve was bicuspid and severely calcific. After resection of the aortic leaflets, an aneurysm of the IVMS was incidentally observed during surgery. The unruptured aneurysm was approximately 6×10×5 mm in size (Figure 1). The IVMS aneurysm was closed by direct suture. Interrupted and pledgeted mattress stitches were applied to close the aneurysmal tissue through the aortic side (Figure 2). Aortic valve replacement was performed with a bileaflet mechanic prosthetic valve. Postoperative recovery was uneventful. At six-year follow-up, he was well.

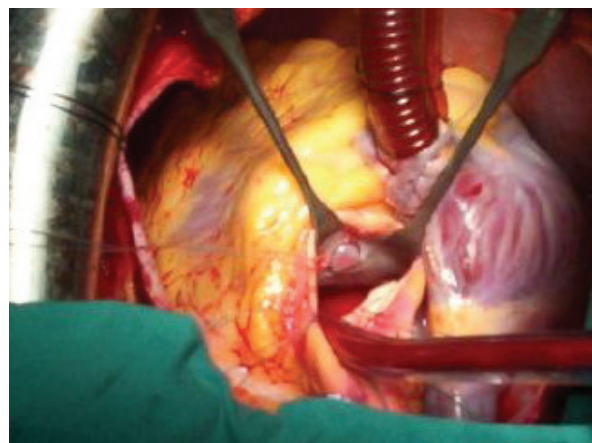


Figure 1. Aneurysm of the interventricular membranous septum is shown

Authors' affiliation: ¹Department of Cardiovascular Surgery, Bursa Yüksek İhtisas Education and Research Hospital, Bursa, Turkey

Corresponding author and reprints: Senol Yavuz MD, Department of Cardiovascular Surgery, Bursa Yüksek İhtisas Education and Research Hospital, 16330, Bursa, Turkey.

Tel: +90-224-360-5050, Fax: +90-224-360-5055, E-mail: syavuz@ttmail.com

Accepted for publication: 30 September 2009

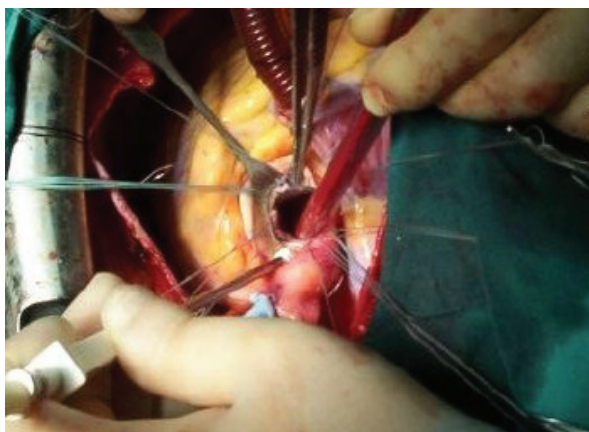


Figure 2. Interrupted and pledgeted mattress stitches were applied to close the aneurysmal tissue through the aortic side

Discussion

Aneurysm of the IVMS is a congenital cardiac anomaly often associated with ventricular septal defect. It is a very rare condition in the absence of ventricular septal defect. The ventricular portion of the membranous septum may be well developed, thickened and perforated by one or many holes, forming an aneurysm of the membranous septum that bulges toward the right in systole. This aneurysm remains intracardiac and it rarely extends outside of the heart.²

Ventricular septal aneurysm is simulated on angiography by a much more common tethered anterior leaflet, and the involved and usually fused chordae.

Aneurysm of the IVMS may be an uncommon occult cardiac source of cerebral embolism. It is generally asymptomatic, and clinical examination and electrocardiogram fail to expose its presence.

Diagnosis may be made by Doppler two-dimen-

sional echocardiography and cardiac catheterization. It also may be confirmed by surgery. On a two-dimensional echocardiographic study, a curvilinear echo in the proximal interventricular septum, bulging toward the right ventricle in systole and visualized in different planes, is an important finding in the diagnosis of an IVMS aneurysm.³ In our case, this disorder was incidentally observed during surgery.

Patients with aneurysm of the IVMS who are asymptomatic must be followed closely. They may incur potential cardiac complications, such as aortic valve prolapse, right ventricular outflow obstruction, tricuspid valve insufficiency, arrhythmia, rupture, thromboembolism, and bacterial endocarditis.⁴

This disorder, alone, is rarely treated surgically. Concurrent heart diseases, hemodynamic abnormalities and aneurysm-related complications require surgical intervention.

References

1. Lazarev SM, Matsan VI. Aneurysm of the membranous heart septum. *Kardiologia*. 1989; **29**: 36 – 40.
2. Sugioka K, Watanabe H, Gersony DR, Hozumi T, Homma S, Suehiro S, et al. Giant aneurysm of the membranous ventricular septum extending outside the heart: diagnosis by transthoracic color flow Doppler echocardiography. *J Am Soc Echocardiogr*. 2002; **15**: 188 – 191.
3. Canale JM, Sahn DJ, Valdes-Cruz L, Allen HD, Goldberg SJ, Ovitt TW. Two-dimensional echocardiography in the study of aneurysms of the membranous interventricular septum. *Arch Inst Cardiol Mex*. 1981; **51**: 153 – 158.
4. Yilmaz AT, Ozal E, Arslan M, Tatar H, Ozturk OY. Aneurysm of the membranous septum in adult patients with perimembranous ventricular septal defect. *Eur J Cardiothorac Surg*. 1997; **11**: 307 – 311.