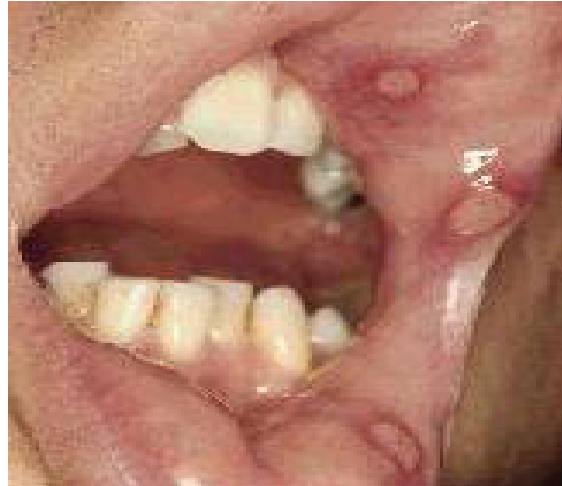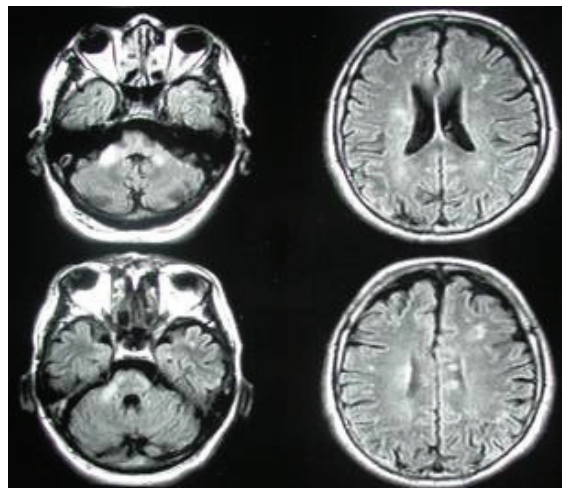


## Photoclinic



**Figure 1.** Oral ophthalmic lesions of the patient



**Figure 2.** Brain MRI of the patient

**A** 56-year-old male was referred to Al Zahra Hospital, Isfahan, Iran, with progressive pseudo bulbar palsy. On admission, he also had hyper-reflexia, urinary incontinence, and gait problems.

The patient had a positive history of recurrent skin,

oral, and genitalia lesions since three years ago (Figure 1).

Multiple periventricular signal changes were seen on brain MRI (Figure 2).

Abbas Ghorbani MD<sup>1</sup>, Bahareh Bazooyar<sup>2</sup>

**Authors' affiliations:** <sup>1</sup>Department of Neurology, School of Medicine, Isfahan University of Medical Sciences, Isfahan, Iran. <sup>2</sup>Department of Neurology, Isfahan University of Medical Sciences, Isfahan, Iran.

**Corresponding author and reprints:** Abbas Ghorbani MD, Al Zahra Hospital, Soffeh St., Isfahan, Iran. Fax: +98-311-625-5555, E-mail: ghorbani@med.mui.ac.ir

Accepted for publication: 5 February 2009

**What is your diagnosis?  
See the page 366 for diagnosis.**

## Photoclinic Diagnosis:

## Behçet Disease

Behçet disease is a systemic disorder characterized by recurrent painful aphthous like ulcers and intraocular inflammation. The clinical triad of uveitis with recurrent oral and genital ulcers bears the name of Hulusi Behçet, a Turkish dermatologist who described three patients who had this triad.

The cause and pathogenesis of Behçet disease remain unknown; however, the tumor necrosis factor alpha (TNF-alpha) pathway is likely involved in the pathophysiology of Behçet disease.

The prevalence of Behçet disease is estimated to be only one case per 300,000 annually. Behçet disease occurs worldwide, with predominance among Asians, North Africans, and Europeans who live between the latitudes of 30 – 45°N. Ocular involvement is seen in about 70% of the patients who have Behçet disease. Recurrent painful oral aphthous ulcers are the most common lesions associated with Behçet disease and occur in 99.3% of cases. Cutaneous hypersensitivity is relatively common, occurring in 81.8% of cases. Acnelike lesions or folliculitis occur frequently. Migratory thrombophlebitis also can develop. Recurrent painful genital ulcers occur in 62.8% of cases. Painful swelling with redness of joints occurs in as many as 50% of patients. At least 50% of patients who have Behçet disease develop gastrointestinal symptoms. Thrombophlebitis is found in 15% of these patients and obliterating thrombophlebitis, arterial occlusion as well as aneurysms may occur in blood vessels of all sizes.<sup>1</sup>

Multiple neurologic disorders that involve pyramidal and extra pyramidal tracts, the cerebellum, the cranial nerves, and rarely the peripheral nerves occur more commonly in male patients and in 5 – 30% of cases.<sup>2</sup> Central nervous system manifestations can be divided into two main groups: 1) parenchymal involvement, which includes brainstem involvement, hemispheric manifestations, spinal cord lesions, and meningoencephalitic presentations, and 2) nonparenchymal involvement, including dural sinus thrombosis, arterial occlusion, and/or aneurysms. Peripheral neuropathy and myopathy are relatively rare. Peripheral neuropathy takes the form of polyneuropathy or mononeuropathy multiplex.<sup>3</sup> Parenchymal involvement, elevated protein and/or pleocytosis in the CSF, brainstem involvement, primary or secondary progressive course and relapse during steroid tapering have all been reported.<sup>4</sup> Neurological manifestation is a relatively less frequent complication of Behçet's disease but it produces severe disabilities. It must be considered in differential diagnosis of multiple sclerosis.<sup>5</sup> Neuro-behçet (NBS) may present as acute focal or multifocal CNS dysfunction, and the clinical picture of NBS may resemble multiple sclerosis (MS).<sup>6</sup> Intracerebral hemorrhage is extremely rare.<sup>7</sup> Aseptic meningitis and menin-

geroencephalitis occurs in 20% of cases.<sup>8</sup>

In NBS, magnetic resonance imaging (MRI) is the imaging study of choice and often reveals iso-hypointense lesions in T1-weighted images and hyper intense lesions in T2-weighted images, mostly in the mesodiencephalic junction, cerebellar peduncles, and other parts of the brainstem.<sup>9</sup>

Treatment of the various manifestations of Behçet disease remains controversial because of the paucity of randomized, controlled trials and the absence of standardized outcome measures for this disease. The goals of therapy in Behçet disease are to suppress inflammation, to reduce the frequency and severity of recurrences, and to minimize retinal involvement. To be effective, treatment must be started early. The extent of involvement and disease severity determine the choice of medication. Treatment options include corticosteroids, cytotoxic agents, cyclosporine, and colchicin.<sup>10</sup>

## References

1. Housman MH, Hamzaoui K. Promising new therapies for Behçet's disease. *Eur J Intern Med.* 2006; **17**:163 – 169.
2. Borruat FX. Neuro-ophthalmologic manifestations of rheumatologic and associated disorders. *Curr Opin Ophthalmol.* 1996; **7**: 10 – 18.
3. Akbulut L, Gur G, Alli N, Borman P. Peripheral neuropathy in Behçet disease: an lectroneurophysiological study. *Clin rheumatol.* 2007; **26**: 1240 – 1244.
4. Akman-Demir G, Serdaroglu P, Taşci B. Clinical patterns of neurological involvement in Behçet's disease: evaluation of 200 patients. The Neuro-Behçet Study Group. *Brain.* 1999; **122**: 2171 – 2182.
5. Shjzadeh N, Borhani H A, Samangoie S, Moosavi H. Neuro-Behçet's disease: a masquerader of multiple sclerosis. A prospective study of neurologic manifestations of Behçet's disease in 96 Iranian patients. *Exp Mol Pathol.* 2003; **74**: 17 – 22.
6. Koçer N, Islak C, Siva A, Saip S, Akman C, Kantarci O, et al. CNS involvement in neuro-Behçet syndrome: an MR study. *AJNR Am J Neuroradiol.* 1999; **20**: 1015 – 1024.
7. Foyaca-Sibat H, Ibañez-Valdés L. Neuro-Behçet's Syndrome. *Int J Neurol.* 2002; **2**: 1531 – 1295
8. Bradley WG. *Neurology in Clinical Practice.* 4<sup>th</sup> ed. Austin, TX: Butheeworth; 2004: 1051.
9. Koçer N, Islak C, Siva A, Saip S, Akman C, Kantarci O, et al. CNS involvement in neuro-Behçet syndrome: an MR study. *AJNR.* 1999; **20**: 1015 – 1024.
10. Alpsoy E, Akman A. Behçet's disease; algorithmic approach to its treatment. *Arch Dermatol Res.* 2009; **301**: 693 – 702.