

CASE REPORT

MUCOSAL LEISHMANIASIS: REPORT OF THREE CASES

Reza Yaghoobi MD*, Nasser Hoghooghi-Rad DVM, MS**

* Department of Dermatology, Ahwaz University of Medical Sciences,

**Department of Pathobiology, School of Veterinary Medicine,
Shahid Chamran University, Ahwaz, Iran

Abstract

The leishmaniasis are parasitic infections with various clinical manifestations and great geographical distribution. Mucosal leishmaniasis (ML) is an important problem in Latin America but is rarely encountered in Iran. There has been a report of the involvement of mucosal tissues with *L. major* and/ or *L. tropica* in the Southwest of Iran. In this report, we describe 3 rare clinical presentations of mucosal leishmaniasis, which were treated with meglumine antimoniate (Glucantime). No evidence of recurrence was noted after several years of follow-up.

Keywords • Mucosal leishmaniasis • lip • Iran • Khoozestan

Introduction

Leishmaniasis is a zoonotic disease caused by the *Leishmania* spp. Transmission of the disease occurs through the bite of a sandfly infected with *Leishmania* parasites. The clinical manifestations of leishmaniasis depend on complex interactions resulting from the parasite's invasiveness, tropism, pathogenicity and the host's genetically determined immune response. Clinically, leishmaniasis is divided into visceral, cutaneous (CL) and mucosal syndromes. The *Leishmania* spp. may produce different clinical syndromes and each syndrome may be caused by more than one species.¹

Mucocutaneous leishmaniasis (espundia) caused by *Leishmania braziliensis* is endemic in most areas of South America.² In the old-world leishmaniasis, mucosal involvement is seen occasionally because of the contiguous spread of cutaneous lesions caused by *L. tropica* or other *Leishmania* spp. This type is also observed in some patients with visceral leishmaniasis, particularly those suffering from concurrent HIV infection.³

Mucosal leishmaniasis (ML) while an important

problem in Latin America¹, is rarely encountered in Iran. We describe 3 different cases of ML in Iran, which were diagnosed on the basis of clinical and histopathological findings.

Case Reports

Case 1

A 57-year-old man residing in the city of Ahwaz, Southwest of Iran, was admitted to our clinic with an oral mass since 4 years. Initially, the patient had noted swelling of the upper lip which gradually developed into a hypertrophic mass on the hard and soft palates (Figure 1), so that he had difficulty with speaking and swallowing. Two separate biopsies were taken within one year and the diagnosis of sarcoidosis was made histologically. The initial treatment with prednisolone failed. A third biopsy revealed Leishman bodies in the lesion and the diagnosis of ML was confirmed. Treatment with systemic meglumine antimoniate and low-dose prednisolone resulted in a cure within 2 weeks. No evidence of recurrence was noted after 6 years of follow-up.

Case 2

A 6-month-old male infant residing in Shoosh, Khoozestan, was referred to our hospital with a 45

•Correspondence: R. Yaghoobi MD, Department of Dermatology, Sina Hospital, Ahwaz, Iran. Fax: +98-611-5551100.

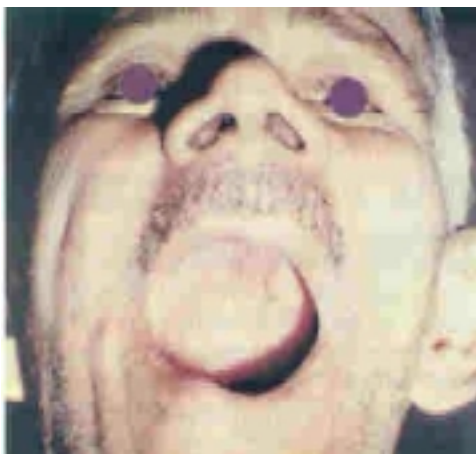

Figure 1. Patient 1: oral mucosal leishmaniasis. Note the ulcer and tumoral mass of soft palate.

day history of lower lip lesion. History of trauma and other medical problems were absent and the lesion had been growing in size over the preceding days.

On examination, the lower lip was found to be partially destroyed and showed a 2x0.7 cm deep red-colored ulcer which was covered with mild hemorrhagic crusts on the borders of the ulcer (Figure 2). Systemic examination was normal. A direct slide smear was prepared from the lesion and microscopic examination of the Giemsa-stained

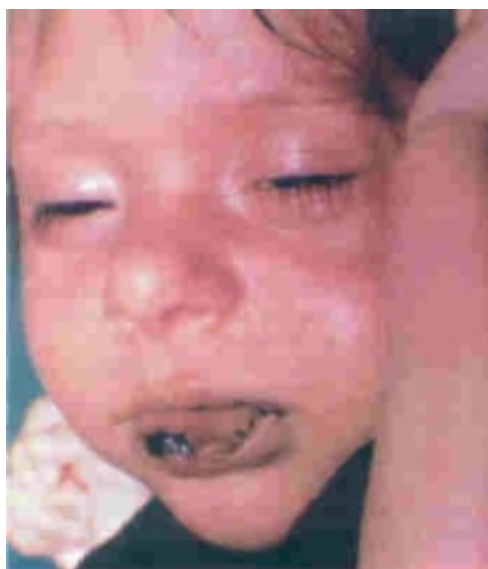

Figure 2. Patient 2: lip leishmaniasis. Partially destructive ulcer on the lower lip.

smears revealed Leishman bodies scattered throughout the slide (Figure 3).

The patient was treated with intralesional injection of meglumine antimoniate in a weekly dose of 20 mg/kg. After 8 injections, complete resolution was noted and no evidence of recurrence was seen after 2 years of follow-up.

Case 3

A 16-year-old boy residing in Behbahan, Khoozestan, presented with a 2-month history of 2 ulcers on the upper and lower lips. No further cutaneous lesions were present on the other parts of the body and no history of trauma or other medical problems was present.

Physical examination revealed 2 erythematous, crusted and indurated ulcers on both upper and lower lips (Figure 4). Direct smears were obtained from the lesions and multiple Leishman bodies were observed. A once-weekly therapy with intralesional meglumine antimoniate (Glucantime) resulted in complete remission after 3 months. The primary lesions healed without any scar or pigmentation and no relapse occurred after one year of follow-up.

Discussion

Human leishmaniasis is transmitted by sandflies. It is usually classified as cutaneous, mucocutaneous and visceral, but the species responsible for visceral disease may also cause skin lesions.³ *L. major*, *L. tropica*, *L. aethiopica* and *L. infantum* are the causative agents of the old world CL whereas *L. braziliensis* and *L. donovani* are responsible for mucocutaneous leishmaniasis in South and Central America and visceral leishmaniasis throughout the world, respectively.^{1,3}

Mucosal lesions have been observed in patients with CL produced by the old world Leishmania species, i.e. *L. infantum* seen in the Mediterranean basin, Middle-East, China and Central Asia, and rarely in case of CL due to *L. aethiopica* and *L. perruviana*. In such cases, if the lesion is situated around the mouth or nose. It may spread across the mucocutaneous margins and expand along the lips or nose without causing any severe destructive lesions similar to the ulcers caused by *L. braziliensis* in South America.⁴

Mucosal disease is relatively rare with the other species. However, there is one report of the involvement of mucosal tissue with *L. major* and or *L. tropica* from the Southwest of Iran, where 17

Mucosal Leishmaniasis: Report of 3 Cases

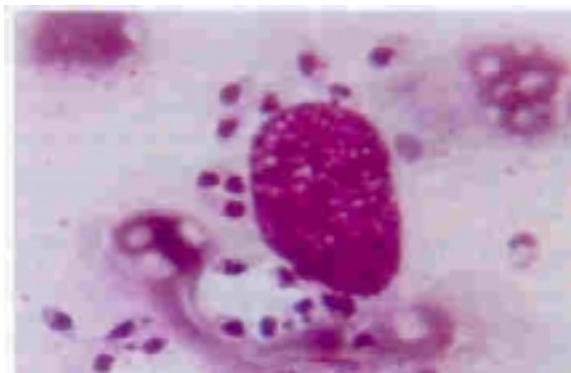


Figure 3. Smear from ulcerated lesion reveals diagnostic Leishman bodies within macrophage (Giemsa stain, x1000).

cases (0.59%) of lip lesions were diagnosed out of a total of 2,861 cutaneous leishmaniasis cases.^{5,6}

Oral mucosal involvement seen in case 1 may have resulted either by direct contiguous spread from the swollen upper lip or by hematogenous spread as reported by Josbi, et al⁴ who speculated an extension of the lesions into mucosal tissues in their patient. As mentioned above, however, the severe destruction of the lower lip of case 2 does not resemble that of case 3 in which mucosal involvement was due to CL of the old-world type.

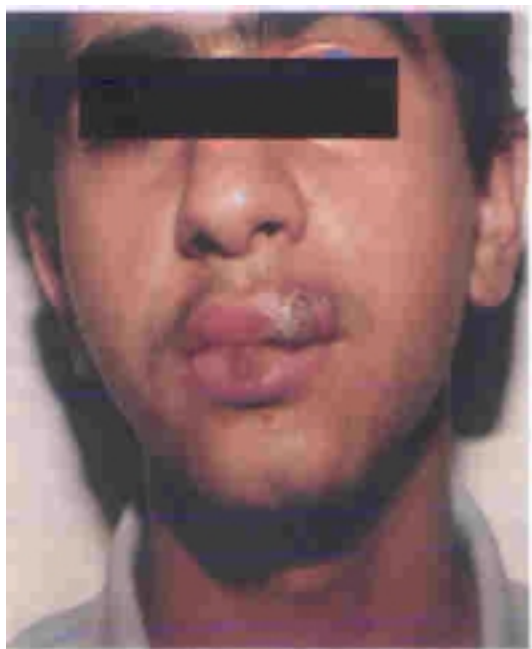

Figure 4. Lip leishmaniasis. Firm and crusted nodules on the lips (patient 3).

In Southwest Iran, the epidemiological and clinical features of CL differ from other areas of this country, where they appear to be similar to Rajasthan in India.⁷ In addition, it seems that some different isolates of *L. major* or *L. tropica* exist in Khoozestan. Moreover, *Phlebotomus* spp. which is responsible for transmission of the promastigote forms of *Leishmania* spp. may increase the pathogenicity of the parasite as to invade the adjacent mucosal tissues.⁷ We presume that these isolates may also be prevalent in neighboring countries of the Persian Gulf. In order to elucidate the epidemiological features as well as the clinical aspects of CL, especially the involvement of mucosal tissues, it is suggested that more surveys be carried out not only on the isolates of leishmania strains by isoenzyme antibody detection and PCR procedures, but also on the *Phlebotomus* spp. and animal reservoirs as well.

Acknowledgments

We would like to thank Dr. Parviz Toosi, Professor of Dermatology, and Dr. Farhad Malekzad, Assistant Professor of Dermatology, for their clinical advice and guidance.

References

- 1 Pearson RD, Sousa AQ, Jeronimo SMB. Cutaneous and mucosal leishmaniasis. In: Gerald L, Mandell JE, Bennett RD, eds. *Mandell, Douglas and Bennett's Principles and Practice of Infectious Diseases*. Vol 5. 5th ed. Philadelphia: Churchill Livingstone; 2000: 2831-41.
- 2 Sanguenza OP, Sanguenza JM, Stiller MJ, Sanguenza P. Mucocutaneous leishmaniasis: a clinicopathologic classification. *J Am Acad Dermatol*. 1993; **28**: 927-32.
- 3 Bryceson ADM, Hay RJ. Parasitic worms and protozoa. In: Rook A, Wilkinson DS, Ebling FJG, Champion RH, eds. *Rook/Wilkinson/Ebling Textbook of Dermatology*. Vol 5. 6th ed. Oxford, UK: Blackwell Science Ltd; 1998: 1411-4.
- 4 Josbi A, Agarwal S, Garg VK, et al. Severe mucosal involvement in a patient with cutaneous leishmaniasis from Nepal. *Int J Dermatol*. 2000; **39**: 317-8.
- 5 Yaghoobi R, Toosi P, Malekzad F. Report of a case of mucosal leishmaniasis. *Nabz*. 1996; **5**: 35-7.
- 6 Yaghoobi R, Hoghooghi-Rad N. Lip leishmaniasis in the Southwest of Iran during the last decade. *Iranian J Dermatol*. 1997; **1**: 19-23.
- 7 Ardehali S, Rezai HR, Nadim A. Epidemiology of leishmaniasis in Iran. In: *Leishmania and Leishmaniases*. Iran, Tehran: University Publication Center; 1985: 149-75.