

CASE REPORT

FAMILIAL ACTINIC LICHEN PLANUS: CASE REPORTS IN TWO BROTHERS

Shahriar Sadr-Ashkevari MD*

Department of Dermatology, Razi Medical Center, Rasht, Iran

Abstract

We report two cases of a 17- and 19-year-old brothers from Rasht (North of Iran), who presented with actinic lichen planus lesions. The younger brother had typical annular patches on his forehead and neck and violaceous papules on his neck. The second brother presented with pigmented melasma-like lesions on his face. Histopathologic studies revealed lichen planus-like eruptions. Many reports describe the tendency of familial lichen planus (LP) developing at an early age and to becoming severe or chronic, and having widespread atypical manifestations. Our report probably is the first, which describes familial occurrence of actinic LP and adds further evidence to the possible role of genetic factors in triggering and determining different types of LP other than the disease itself.

Keywords • Lichen planus • familial • actinic • Iran

Introduction

Lichen planus (LP) is a unique papulo-squamous dermatosis which may present with mucocutaneous lesions. It shows wide variation both clinically and histopathologically.

Factors including the consumption of various drugs or contact with heavy metals, systemic diseases, graft-versus-host disease, autoimmune liver disease, ulcerative colitis and myasthenia gravis^{1,2} have been implicated in the etiology of LP. These data suggest concurrent immunologic triggering and genetic susceptibility in the pathogenesis of LP.^{1,3-6}

LP has been reported worldwide, but is more prevalent among the younger age groups in both tropical and subtropical countries, with a predominance of some clinical types such as actinic LP that has been reported mostly in the Middle East and Asia.⁷⁻⁹

In addition, LP has been reported in families^{3,10,11} and monozygotic twins, with an incidence of 1% to 11% of all LP cases. It has been characterized by its tendency to develop at an early age, become severe or chronic, and to have widespread atypical manifestations.^{3,10,11,12}

* Correspondence: S. Sadr-Ashkevari MD, Razi Medical Center, Sardar Jangal Avenue, Rasht, Iran. Fax: +98-131-5559787.

Case Presentation

Two Iranian brothers from northern Iran were referred to the Dermatology Department of Razi Medical Center in Rasht with cutaneous eruptions, both clinically and histologically compatible with actinic LP, in the summer of 1997.

Case 1

A 19-year-old male patient presented with brownish erythematous melasma-like patches, 2 x 3.5-4 cm in size, on his temporal and malar regions (Figure 1). The lesions had been present since 2 years prior to admission, but had shown aggravation during the summer with mild pruritus. The patient had not used any medications and no systemic disease was evident. Physical examination revealed no signs of LP in the other parts of the body, including the oral mucosa, hair or nails.

Case 2

A 17-year-old male patient (brother of case 1) presented with well-defined brownish erythematous patches with mild central atrophy on his forehead, glabella, nose, upper lip and sides of neck. These lesions varied in size and some, especially those on the sides of the neck, were annular in shape. A few typical LP papules were

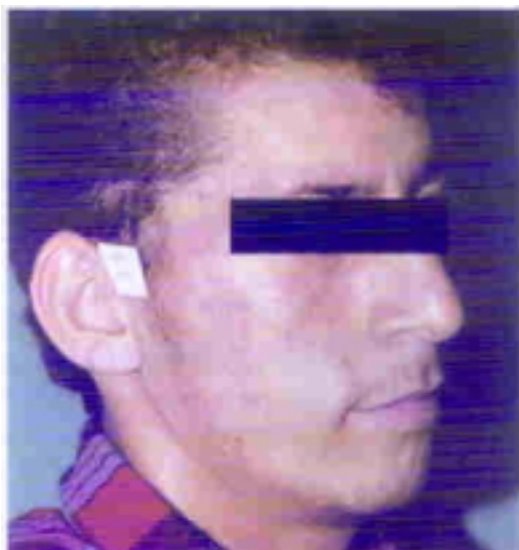

Figure 1. Melasma-like brownish erythematous patches on the face and temple (Case 1).

present on the neck and submandibular area (Figure 2). The lesions had been present since 4 months prior to admission and had shown exacerbation on sun exposure during the summer when the patient experienced mild pruritus. Like his brother, this patient had no history of using any medications and features of other diseases

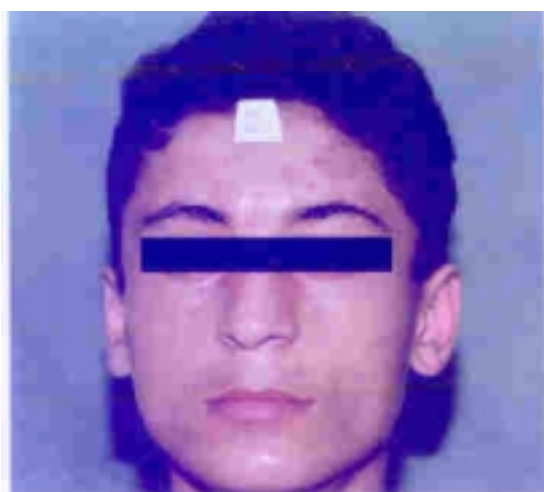

Figure 2. Brownish erythematous patches with mild annular configuration on the forehead, glabella and upper lip (Case 2).

absent. On physical examination, no evidence of LP was present in the other parts of the body.

Histopathologic studies of the biopsy specimens derived from the lesions revealed findings compatible with those reported for actinic LP, including mild to moderate degrees of liquefaction, degeneration of the epidermal basal cell layer, moderate band-like to moderate perivascular lymphocytic infiltration of the upper- and mid-dermis and significant pigmentary incontinence (Figures 3 and 4).

Discussion

It is assumed that LP results from a delayed type of hypersensitivity reaction against an unknown new epidermal antigen that develops either alone or concurrent with other diseases. Infective, psychosomatic, metabolic, pharmacologic, autoimmune, and genetic factors have been implicated in the etiology of this disease.^{1,2,4}

Reports exist on the occurrence of LP in families and monozygotic twins. Higher incidence of HLA-DR1 is detected in such patients.^{3,5,6,12}

The familial occurrence of LP is a well-recognized but rare event, with an incidence varying from 1% to 11% of all LP patients. In comparison with classic LP, familial LP is characterized by its early age of onset, atypical and widespread clinical presentation and its higher tendency to become severe and chronic.¹⁰⁻¹³ Sodaify, in 1978, reported one of the largest familial groups of LP, including a Jewish mother and five of her nine children in Shiraz, without increased incidence of HLA class 1 phenotypes.¹²

On the other hand, actinic LP is a distinct variant characterized by annular erythematous brownish patches or plaques. In a few cases isolated or confluent papules, hypermelanotic melasma-like patches are confined to exposed parts of the skin, particularly the face, or even a dermatitis that occurs predominantly in Oriental (especially Middle Eastern) young people.⁷⁻¹² Histologic findings reveal an interface dermatitis, mostly in the form of mild vacuolar degeneration of the basal layer, perivascular lymphocytic infiltration of the mid-dermis and significant pigmentary incontinence. The incidence of actinic LP was reported to be 0.9% in our previous study which was conducted on 110 cases of LP.¹⁴

With regard to this report, and to the occurrence of actinic LP in an Egyptian boy who had been living in England all his life¹⁵, it is proposed that

Familial Actinic Lichen Planus

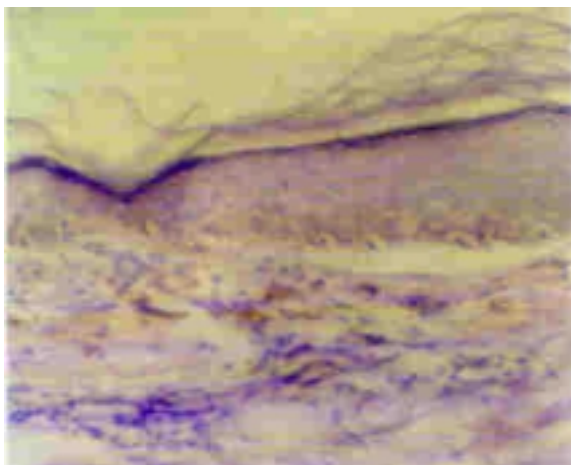


Figure 3. Basal cell degeneration, mild to moderate perivascular infiltration of lymphocytes and significant pigmentary incontinence (Case 1).

these case reports are not only the first on familial occurrence of actinic LP in the world, but also reveal further evidence that genetic factors

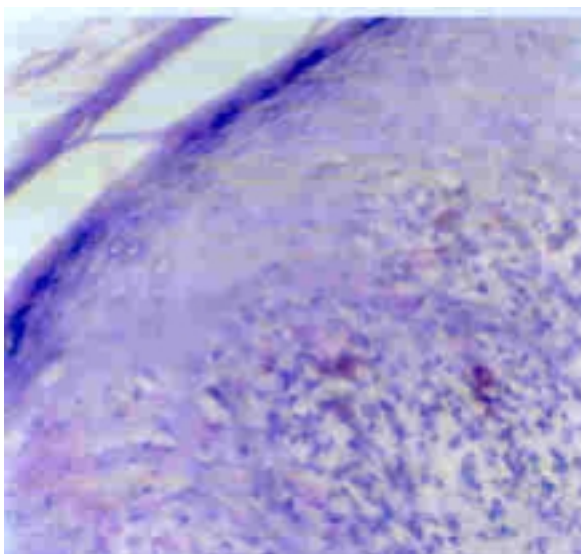


Figure 4. Severe basal cell degeneration with pigmentary incontinence and typical band-like infiltration of lymphocytes close to epidermis (Case 2).

(especially HLA-DR1) may be involved, somehow specifically, in the occurrence of LP and even its clinical appearance,^{3-6,10,12,13} a matter that must be confirmed through further studies.

With regard to the clinical melasma-like presentation in one of our cases, we agree with Al-Fuzan who suggested the inclusion of pigmented actinic LP in the differential diagnosis of patients presenting with facial melanosis.⁸

Acknowledgment

The author would like to thank Miss Leila Zadparast for her cooperation processing and typesetting of the manuscript.

References

- 1 Scully C, El-Kom M. Lichen planus; review and update on pathogenesis. *J Oral Pathol.* 1985; **14**: 431-58.
- 2 Graham-Brown R. Lichen planus and lichen-planus-like reaction. *Br J Hosp Med.* 1986; **36**: 281.
- 3 Koefoed HL, Wantzin GL. Familial lichen planus: more frequent than previously suggested? *J Am Acad Dermatol.* 1985; **13**: 50-4.
- 4 Shai A, Halevy S. Lichen planus and lichen planus-like eruption: pathogenesis and associated diseases. *Int J Dermatol.* 1992; **31**: 379-84.
- 5 Powell FC, Rogers RS, Dickson ER, Moore SB. An association between HLA-DR1, and lichen planus. *Br J Dermatol.* 1986; **114**: 473-8.
- 6 Valsecchi R, Bontempelli M, Rossi A, et al. HLA-DR and DQ antigens in lichen planus. *Acta Derm Venereol.* 1988; **68**: 77-80.
- 7 Dengezli H, Nouira R, Jomaa B. Actinic lichen planus. Anatomoclinical study of 10 Tunisian cases. *Ann Derm Venereol.* 1994; **121**: 543-6.
- 8 Al-Fuzan AS, Hassab-el-Naby HM. Melasma-like (pigmented) actinic lichen planus. *Int J Dermatol.* 1992; **31**: 413-5.
- 9 Salman SH, Kibbi AG, Zaynoun S. Actinic lichen planus. A clinicopathologic study of 16 patients. *J Am Acad Dermatol.* 1989; **20**: 226-31.
- 10 Lin AN, Srolovitz H, Billick RC. Familial lichen planus. *Cutis.* 1986; **37**: 135-6.
- 11 Mahood JM. Familial lichen planus. A report of nine cases from four families with a brief review of the literature. *Arch Dermatol.* 1983; **119**: 292.
- 12 Sodaify M, Vollum DI. Familial lichen planus: a case report. *Br J Dermatol.* 1978; **579**: 82.
- 13 Katzenelson V, Lotem H, Sandbank H. Familial lichen planus. *Dermatologica.* 1990; **180**: 166-8.
- 14 Sadr-Ashkevari S, Mansoori-Ghiasi MAN, Darjani A. A look to clinical appearance of lichen planus in Guilan. Study of 110 cases. *Med J Guilan Univ Med Sci.* 1997; **18**: 1-6.
- 15 Mc Farlane AW. A case of ALP. *Clin Exp Dermatol.* 1989; **14**: 65-8.