

ORIGINAL ARTICLE

ABSENCE OF RADIAL PULSE IN DISPLACED SUPRACONDYLAR FRACTURE OF HUMERUS IN CHILDREN

Farid Ghasemzadeh MD^{*}, Keivan Ahadi MD, Ali Rahjoo MD, Parviz Habibollahzadeh MD

*Department of Orthopedic Surgery, Sina Hospital,
Tehran University of Medical Sciences, Tehran, Iran*

Abstract

Background-Supracondylar fracture of the humerus is a relatively common injury in children and is the most common fracture in this age that requires surgery. Absence of the radial pulse is not a rare accompanying sign of this type of fracture. Cases displaying this condition are occasionally referred to centers with vascular and orthopedic surgery facilities, including Sina Hospital, a trauma referral center, downtown Tehran. The patients are dispatched to these centers with minimum intervention at the time of presentation. This act will lead to undue loss of time and patient inconvenience. The present study was designed to establish a logical approach to this important orthopedic emergency.

Methods-Out the 61 patients admitted for displaced supracondylar fracture over a 5-year interval, 21 had absent radial pulse. The orthopedic or vascular surgery interventions along with the aftermath were studied.

Results-From the 21 patients with absent radial pulse, vascular surgery had been performed only in 4 patients. Exploration of vessels was normal with spasm and without structural injury or occlusion in 2 cases. Venous graft for repair was done in the other 2 cases who had delayed capillary filling. In the remaining 17 patients with normal capillary filling, vascular surgery had not been performed and therapeutic results were satisfactory.

Conclusion-In a child with a displaced supracondylar fracture of the humerus and absent radial pulse, the presence of normal capillary filling, similar to the other limb, is a reliable sign for effective circulation. With this finding, the orthopedic surgeon can manage the patient without vascular surgery facilities. Delayed capillary filling however needs emergency vascular surgery consultation.

Keywords • Humerus • supracondylar fracture • vascular injury

Introduction

Supracondylar fracture of the humerus is a relatively common fracture in children and is the most common fracture in childhood that requires surgery.¹ Brachial artery injury is estimated to comprise between 2.5% and 38% of all orthopedic injuries in different studies.^{2,3,4} In orthopedic practice, we frequently witness a child with this injury and absent radial pulse who is referred to a hospital equipped for

vascular surgery facilities.

To our knowledge, the reason for most referrals is mainly the absence of a vascular surgeon. Referring such patients imposes unnecessary physical, psychological and economical stress to the patient, their parents, and to the health system. Delayed management also adds to the patient's problems.

It is therefore necessary to be familiar with the diagnostic and therapeutic approach to a patient with supracondylar fracture of the humerus and absent radial pulse. Also it is important to know whether referral is required in all such cases. It should be stated that in developing countries

^{*} **Correspondence:** F. Ghasemzadeh MD, Department of Orthopedic Surgery, Sina Hospital, Tehran University of Medical Sciences, Tehran, Iran. E-mail: faridghasemzadeh@yahoo.com.

including Iran, vascular surgery centers are not so accessible.

Despite of different views stated in the literature concerning this injury, the prevailing agreement among most references is presented as follows.⁴⁻¹² For estimation of the circulatory status of an injured limb, in spite of the recent technological improvements, the physical examination has a central role. Palpating the radial pulse, checking the capillary filling (CF) time compared with the opposite limb and painless active muscle movement that indicates sufficient muscular circulation are among the most important examinations in evaluating the condition.

The purpose of the present study was to present a diagnostic and therapeutic approach to children with supracondylar fracture of the humerus and absent radial pulse, considering the limited vascular surgery centers in Iran. The focus of this study is on CF as an important sign of efficient limb circulation.

Patients and Methods

This study was conducted from January 1994 to August 2000. A total of 61 patients, consisting of 50 (82%) boys and 11 (18%) girls who were aged less than 18 and had been admitted to Sina Hospital, Tehran, Iran, with a diagnosis of displaced supracondylar fracture of the humerus (type 3) were studied. Data was obtained from the patients' medical records. The patients were divided into 2 groups; group one included patients with absent radial pulse (n=21) and group two included those with intact radial pulse (n=40).

For both groups, a complete neurovascular examination was performed and the CF time of the injured limb was evaluated by exerting pressure on the pulp and nail bed of the digits and then compared with the opposite side. The patients with an absent pulse had normal or delayed CF time. Vascular surgery consultation was performed for all the absent pulse group.

Vascular surgery treatment modalities were classified as follows: observing patients with normal CF. These patients (n=14) received the necessary orthopedic treatments, exploring the brachial artery in patients with delayed CF (n=2), and exploring the brachial artery in selected patients with normal CF (n=2).

The difference between the beliefs of vascular surgeons, as well as controversies in the literature toward performing vascular surgery, led to

different surgical protocols.

Orthopedic treatment modalities were classified as follows: closed reduction with percutaneous pinning, open reduction and internal fixation (ORIF) by the posterior or lateral approach, skeletal traction using olecranon pin and casting, skeletal traction using olecranon pin and then ORIF by the posterior approach.

Skeletal traction was performed in patients with absent radial pulse and severe soft tissue edema, comminution of fracture site and significant skin abrasion. These conditions had made the surgical procedure difficult and harmful to perform.

The patients were followed up for a minimum of one month after admission. In addition, 10 patients from the first group, were re-examined after 1 to 3 years.

Student *t-test* and Fischer exact test were used for statistical analysis.

Results

There was no significant difference ($p=0.65$) between the age of the patients in either group.

From the 21 patients with absent radial pulse, only 2 had delayed CF and 4 received vascular surgery interventions. The reason for surgery in two patients with normal CF was that after emergency reduction, no recovery in pulse was seen. In the first case, skeletal traction lead to neurological deficit of the hand and emergency brachial artery exploration was performed along with median nerve exploration and then open reduction and internal fixation of the fracture. The pulse returned to normal after surgery. In the second case, after a few hours of skeletal traction, the pulse did not return but CF was normal. According to the surgeon's preference, exploration of the artery was performed and it was found to be only spastic. Exploration of the brachial artery was also performed in two patients with delayed CF at the time of hospitalization. In the first case, the artery was sectioned and then repaired with a venous graft. Although a venous graft was placed two times, the pulse did not return to normal. However, CF returned to normal and the patient was discharged without a radial pulse or ischemia. In the other case, the difference between intimal tearing and spasm was doubtful and venous bypass grafting was performed.

In the other 17 patients with absent radial pulse, the only treatment modality for absent pulse was observation and orthopedic intervention was

Absence of Radial Pulse in Supracondylar Fracture

performed.

Orthopedic treatment was the same in both groups except for skeletal traction, which was performed mostly in those without a radial pulse. Skeletal traction was performed in cases with comminuted fractures and significant edema of the limb. No signs of compartment syndrome were seen.

Radial pulse returned immediately after reduction in 14 (66.7%) patients, it returned within one week after reduction in four (19%) and immediately after arterial repair in one (4.8%) patient.

In the other 2 patients, the pulse did not return until 1 week and in one patient CF returned to normal after performing venous bypass grafting two times. No ischemic signs were seen in this patient. In the other case, the pulse did not return to normal after 3 weeks of olecranon traction. However, CF returned to normal without any signs of ischemia. These two patients had not been followed up after 1 month.

Ten of the patients with no radial pulse were visited again after one to three years and limb circulation or range of the joint movement were noted to be satisfactory.

Discussion

The majority of patients (21 of 61 patients) with absent radial pulse, were those who had been referred to our center.

Vascular repair was performed only on 2 of 4 patients with absent radial pulse because of delayed CF time. In the other 2 patients with normal CF before surgery, exploration did not show any structural injury or brachial artery occlusion. In other words, there was no sign of ischemia in these patients before surgery. The other 17 patients with absent radial pulse but normal CF at the time of admission had no circulatory compromise in the treatment period and the pulse returned in all but one patient who had no ischemic limb after one month.

Some authors^{5,6} consider CF as the main indicator of normal limb circulation in supracondylar fracture. However, painless muscle activity is believed to be the main sign of efficient limb circulation by others.⁷ We relied on CF more than the latter for estimating the status of limb circulation. We believe that estimation of muscle activity after closed or open reduction in an anesthetized patient is not possible, especially

when one decides to perform vascular surgery at the time of the anesthesia.

In addition, in younger children, severe pain and agitation both preclude precise estimation of muscle activity.

The short follow-up of some patients is a limitation for this study, although most vascular complications appear shortly after operation.

Since a uniform approach was not applied toward this condition by the orthopedic and vascular surgeons and access to the image intensifier in the operation rooms was difficult, some times closed reduction and percutaneous pinning was made impossible in some patients. Both these factors influenced our inferences about the results.

The occurrence of compartment syndrome must never be ignored in any stage of treatment. Most authors do not recommend angiography.^{7,13} Emergency exploration of the brachial vessels is indicated in the following cases: those with compromised vasculature in the site of open fractures, patients with an irreducible fracture and intact radial pulse, which disappears with an attempt on reduction, and those with a reducible fracture with no pulse or signs of muscle ischemia after reduction.

Vascular exploration with anteromedial approach may lead the surgeon to perform arterial repair with a venous graft. In cases with arterial spasm, only attempts on relieving the spasm are recommended. Regarding the setting in which the radial pulse fails to return after reduction while the CF is normal and signs of ischemia are absent, the authors have different opinions and three approaches have been recommended.

The first approach is continued close observation, suggested by Gillinham and Rang¹⁴ who stated that the pulse usually returns within 10 days. The second approach is observation of the patient for 24 to 36 hours and performance of a delayed arteriogram and surgical repair of vessels, if indicated.⁷ The third approach is immediate exploration of the brachial vessels and correction of vascular pathology.^{7,9,10}

According to the above-mentioned findings, we suggest that CF is a useful sign for estimating sufficient circulation in supracondylar fracture of the humerus in children. The orthopedic surgeon can treat patients with normal CF and absent radial pulse in situations in which no vascular surgery is possible. Emergency vascular surgery consultation in the case of absent radial pulse and delayed CF is

necessary but if the vascular surgeon is not accessible to resolve the problem of the brachial artery during the golden time, emergency reduction of the fracture is suggested.

As the major arteries to the elbow and forearm region come from the anteromedial side, we

recommend lateral or posterior approach in patients with normal CF if no vascular exploration is done.¹⁵

The summary of our recommendations for approach to such patients has been presented as an algorithm in Figure 1.

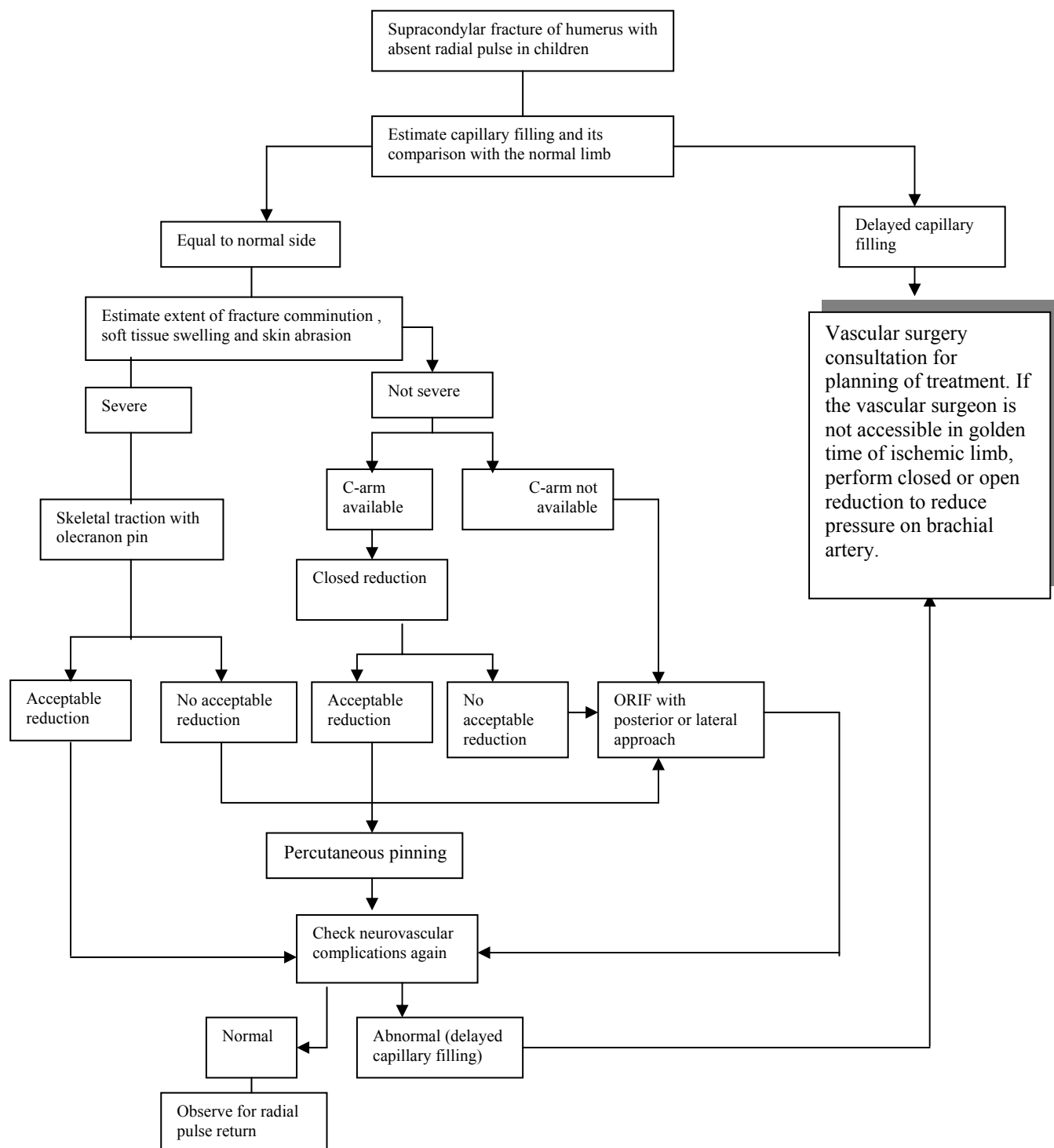


Figure 1. Algorithmic approach to children with supracondylar fracture of humerus with absent radial pulse in Sina Hospital. (Designed by Farid Ghasemzadeh, MD)

Absence of Radial Pulse in Supracondylar Fracture

References

- 1 Hammond WA, Kay RM, Skaggs DL. Supracondylar humerus fractures in children. *AORN J*. 1998; **68**: 186-99.
- 2 Dormans JP, Squillante R, Sharf H. Acute neurovascular complications with supracondylar humerus fractures in children. *J Hand Surg [Am]*. 1995; **20**: 1-4.
- 3 Campbell CC, Waters PM, Emans JB, Kasser JR, Millis MB. Neurovascular injury and displacement in type III supracondylar humerus fractures. *J Pediatr Orthop*. 1995; **15**: 47-52.
- 4 Sabharwal S, Tredwell SJ, Beauchamp RD, et al. Management of pulseless pink hand in pediatric supracondylar fractures of humerus. *J Pediatr Orthop*. 1997; **17**: 303-10.
- 5 Operative treatment of children fractures. In: Chapman MW, ed. *Chapman's Orthopedic Surgery*. 3rd ed. Philadelphia: Lippincott-Williams & Wilkins; 2000: 4180.
- 6 Rang M. *Children's Fracture. With 5 Contributors*. 1st ed. Philadelphia: Lippincott Company; 1974: 101.
- 7 Rockwood CA, Wilkins KE, Beaty JH. *Fractures in Children*. 4th ed. Philadelphia: Lippincott-Raven; 1996: 722-7.
- 8 Canale ST, Campbell WC. *Campbell's Operative Orthopedics*. 9th ed. St. Louis: Mosby; 1998: 2416-7.
- 9 Clement DA. Assessment of treatment plan for managing acute vascular complications associated with supracondylar fractures of humerus in children. *J Pediatr Orthop*. 1990; **10**: 97-100.
- 10 Shaw BA, Kasser JR, Emans JB, Rand FF. Management of vascular injuries in displaced supracondylar humerus fractures without arteriography. *J Orthop Trauma*. 1990; **4**: 25-9.
- 11 Shaker JJ, White JJ, Signer RD, Golladay ES, Haller JA. Special problems of vascular injuries in children. *J Trauma*. 1976; **16**: 863-7.
- 12 Garbuz DS, Leitch K, Wright JG. The treatment of supracondylar fractures in children with an absent radial pulse. *J Pediatr Orthop*. 1996; **16**: 594-6.
- 13 Pirone AM, Graham HK, Krajchich JI. Management of displaced extension-type supracondylar fractures of the humerus in children. *J Bone Joint Surg Am*. 1988; **70**: 641-50.
- 14 Gillinham BL, Rang M. Advances in children's elbow fracture. *J Pediatr Orthop*. 1995; **15**: 414-21.
- 15 Rutherford RB. *Vascular Surgery*. 4th ed. Philadelphia: WB Saunders; 1994: 713-33.