

CASE REPORT

VERRUCOUS CARCINOMA OVERRIDING EUMYCETOMA

Ali-Reza Emami-Naeini MD*, Parvin Dehghan MS**, Reza Imani MD*

*Department of Infectious and Tropical Diseases, **Department of Medical Mycology, Isfahan University of Medical Sciences, Isfahan, Iran

Abstract

Eumycotic mycetoma is a chronic infection of the cutaneous and subcutaneous tissues which also invades the nearby surrounding tissues. Over 70 percent of lesions involve the feet. Herein, we present a male farmer with a chronic eumycetoma of the buttock, which was unnoticed and untreated for about ten years and ultimately become malignant.

Keywords • Carcinoma • Madura foot • fungi • mycetoma

Introduction

Eumycetoma is a form of mycetoma caused by various genera of true fungi. These agents are primarily saprophytic microorganisms found in soil and plant matter.¹ They may be inoculated into the skin or mucosa of healthy persons through thorns, splinters and other plant material.² It is mainly seen in tropical and subtropical areas with a male to female ratio of 5:1. The disease is marked by a chronic progressive cutaneous and subcutaneous infection of the nearby anatomical structures. The foot is the most common site of involvement but the buttock is rarely involved.³ It is characterized clinically by tumefaction, draining sinuses, and colored granules. Color granules may be black or white to yellow.⁴

Case Presentation

A 48-year-old male farmer, residing in a village in eastern Isfahan, central Iran was admitted to Al-Zahra Hospital, Isfahan, in February 2001 with several malodorous, cauliflower-like skin lesions on the upper half of his right buttock (Figure 1). He had noted a small painless skin lesion with yellow discharge on his right buttock ten years presentation. This lesion healed but a cluster of

new lesions emerged at the same site and around it with multiple residual sinus formations. Pain or systemic symptoms were absent. About five months before presentation a series of cauliflower-like lesions appeared on the involved skin. Biopsy was taken, which revealed verrucous carcinoma (Figure 2). Biopsy was also taken from the depth of the lesion and cultured. Results showed that *Paecilomyces* sp (Figure 3) was present. *E. coli* grew on the bacterial culture. Laboratory results including CBC and ESR were normal. Mantoux test done by 5IU PPD-S was negative. The patient received ceftriaxone and ketoconazole and was scheduled for surgery.

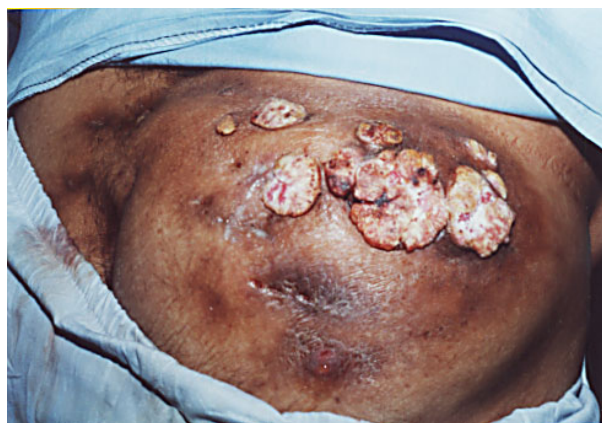

Figure 1. Verrucous carcinoma; white cauliflower lesions.

•Correspondence: A.R. Emami-Naeini MD, Department of Infectious Diseases, Isfahan University of Medical Sciences, Al-Zahra Hospital, Isfahan, Iran, P.O.Box: 914, Fax: +98-311-6691561, E-mail: A_emami35@hotmail.com.

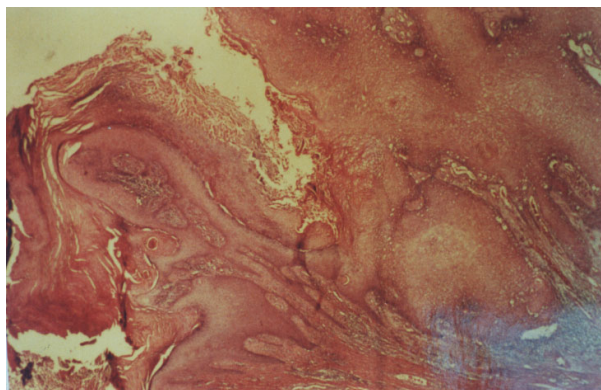


Figure 2. Neoplastic proliferation of squamous cell with hyperkeratosis and acanthosis.

Discussion

Verrucous carcinoma is an uncommon warty, white neoplasm, which is rarely ulcerated.⁵ It is often associated with leukoplakia and is common in tobacco chewers.⁶ Macroscopically, the tumor is an exophytic fungating mass with large fronds. It is usually seen on the mucosa of the oral cavity. Microscopically, the well-differentiated squamous cells are covered by a thick keratinizing layer.⁷ The mycetoma is uncommon in Iran and this patient is a very rare case of this condition. Overriding of this carcinoma on mycetoma is rare and deserves to be considered.

Greater awareness of rare and unusual forms of disease are of importance in facilitating the recognition of similar cases in the future.

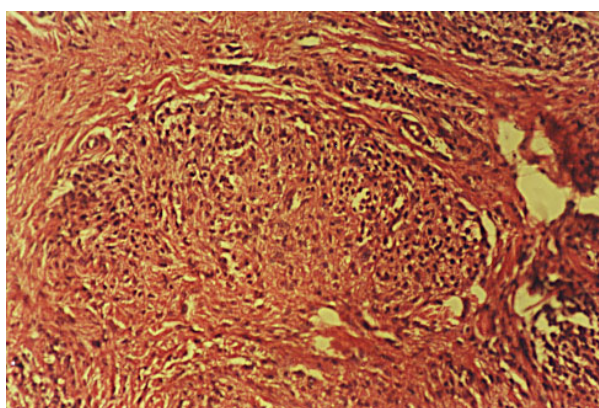


Figure 3. Powdery and pink colonies on Sabouraud and Mycosel agar medium.

Acknowledgment

The authors would like to thank Dr. S. Shadzi and Dr. M. Rostami for their valuable suggestions.

References

- 1 Rippon JW. *Medical Mycology: The Pathogenic Fungi and the Pathogenic Actinomyces*. 3rd ed. Philadelphia: Saunders; 1988: 118.
- 2 Mariat F, Destombes P, Segretain G. The mycetomas: clinical features, pathology, etiology and epidemiology. *Contrib Microbiol Immunol*. 1997; **4**: 1-39.
- 3 Hay RJ, McKenzie DW. Mycetoma in the United Kingdom: a survey of forty-four cases. *Clin Exp Dermatol*. 1983; **8**: 553-62.
- 4 Abbot P. Mycetoma in Sudan. *Trans R Soc Trop Med Hyg*. 1956; **50**: 11-24.
- 5 Hume WJ, Quayle AA. An unusual epithelial neoplasm of gingiva resembling the keratoacanthoma. *Br J Oral Maxillofac Surg*. 1985; **23**: 366-70.
- 6 Rothman K, Keller A. The effect of joint exposure to alcohol and tobacco on risk of cancer of the mouth and pharynx. *J Chronic Dis*. 1972; **25**: 711-6.
- 7 Mashberg A, Barsa P. Screening for oral and oropharyngeal squamous carcinomas. *CA Cancer J Clin*. 1984; **34**: 262-8.