

CASE REPORT

CAUDA EQUINA SYNDROME IN PREGNANCY

Hamed Reihani-Kermani MD

Department of Neurosurgery, Kerman University of Medical Sciences, Kerman, Iran

Although extremely rare, cauda equina syndrome caused by lumbar disc herniation can occur during pregnancy. The author report a case of cauda equina syndrome due to lumbar disc disease occurring during pregnancy, confirmed by magnetic resonance imaging (MRI), where a delay in diagnosis led to persistent neurologic deficit despite surgical treatment. The advent of MRI and modern surgical techniques to treat lumbar disc herniation allow safe management of this condition at any stage of gestation.

Keywords • cauda equina syndrome • lumbar disc disease • magnetic resonance imaging • pregnancy

Introduction

Low back pain is a common complication of pregnancy that has been reported in as many as 56% of women during gestation.¹ In contrast, symptomatic lumbar disc herniation is rare, occurring in only one in approximately 10,000 pregnancies.² Fewer than 2% of patients who undergo surgery for lumbar disc disease with neurologic deficit have cauda equina syndrome,³ characterized by radicular pain, sensorimotor deficits and sphincter involvement. Few cases of cauda equina syndrome caused by lumbar disc herniation during pregnancy have been reported.⁴⁻⁶

This is a report of a case of cauda equina syndrome occurring during pregnancy where a delay in diagnosis led to persistent neurologic deficit.

Case Report

A 26-year-old primigravida nulliparous woman presented at 20 weeks of gestation with a history of low back pain radiating to the left buttock and leg. She presented initially (at 16 weeks of gestation) to a local emergency department but was discharged with pain medication and an exercise plan on the assumption that her pain was typical of normal pregnancy. Four weeks later, she developed

worsening low back pain and bilateral thigh pain associated with claudication and numbness of the perineum and left leg. She noted difficulty in urinating one day before admission and, on the same day, pelvic magnetic resonance imaging (MRI) was performed (Figure 1). The patient was referred to the neurosurgery clinic for further evaluation. On physical examination, she demonstrated a left foot drop gait. She had total paralysis of the left extensor hallucis longus and ankle inversion. Reaction to pinprick was decreased throughout the perineum and along the left L₅ nerve root dermatome. The left ankle reflex was depressed. The straight leg raising test on the left side was positive at a 30° angle because of low back and posterior thigh pain. MRI of the lumbosacral spine demonstrated central disc herniation with extension to the left at L₃-L₄, which almost completely obliterated the spinal canal (Figure 2A and B). The patient underwent standard L₄ laminectomy on the same day. A large disc fragment, displaced into the spinal canal, was removed. In the immediate postoperative period, the patient experienced relief of back and leg pain. Three days postoperatively, she was doing well with partial return of sensation and complete return of bladder function. Her foot drop had not improved at 6 weeks and 3 months of follow-up. She failed to return for further follow-up.

Discussion

Cauda equina syndrome is characterized by

Correspondence: H. Reihani-Kermani MD, Department of Neurosurgery, Kerman University of Medical Sciences, Kerman, Iran. Fax: +98-341-50215, E-mail: reihani2002@yahoo.com.

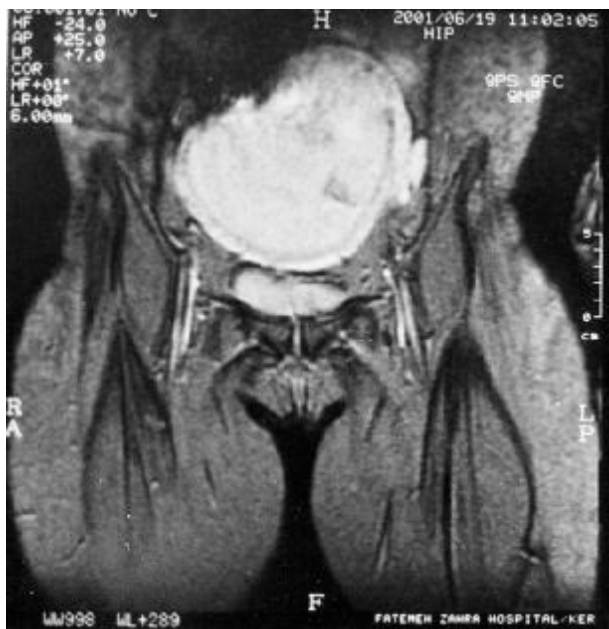

Figure 1. Magnetic resonance image of pelvis (coronal view) demonstrates normal anatomy.

radicular-type pain that may involve the legs, buttocks, perineal and perianal regions. Motor deficits, particularly of the lower neurons, and sensory deficits, generally asymmetrical, are common. Sphincter involvement is a late finding and is usually mild.⁷ Similar symptoms can occur throughout a normal pregnancy, so there is potential for misdiagnosis and consequent delay in treatment.⁸

Although lumbar disc herniation is reported in

only one in approximately 10,000 pregnancies,³ and fewer than 2% of lumbar disc herniations are estimated to result in cauda equina syndrome with severe and/or progressive neurologic deficits, physicians should be aware that these conditions can in fact occur during pregnancy. They constitute an emergency and should be diagnosed and treated promptly without considering the stage of gestation. A poor prognosis is correlated with the length of time from onset to surgical decompression and the intensity of saddle anesthesia, a symptom of cauda equina syndrome.⁴ In the present case, the treating physician was reluctant to submit the patient to diagnostic MRI because the onset of symptoms had occurred at approximately 16 weeks of gestation. The literature clearly demonstrates that pregnancy at any stage is not a contraindication to MRI.⁸⁻¹⁰ In this case, according to the symptoms and signs, pelvic MRI was unnecessary however, the spine MRI was the definitive diagnostic procedure for establishing lumbar disc disease.

Pregnancy at any stage is not considered as a contraindication to surgical intervention.^{8, 11} Since cauda equina syndrome is a surgical emergency, the patient underwent surgery soon, but because of delays in diagnosis, severe neurological deficit (foot drop) did not resolve in 3 months' follow-up. Although pregnant women do not have an increased prevalence of disc abnormalities,^{1, 12} once the clinical diagnosis of lumbar intervertebral disc herniation has been made, the patient would

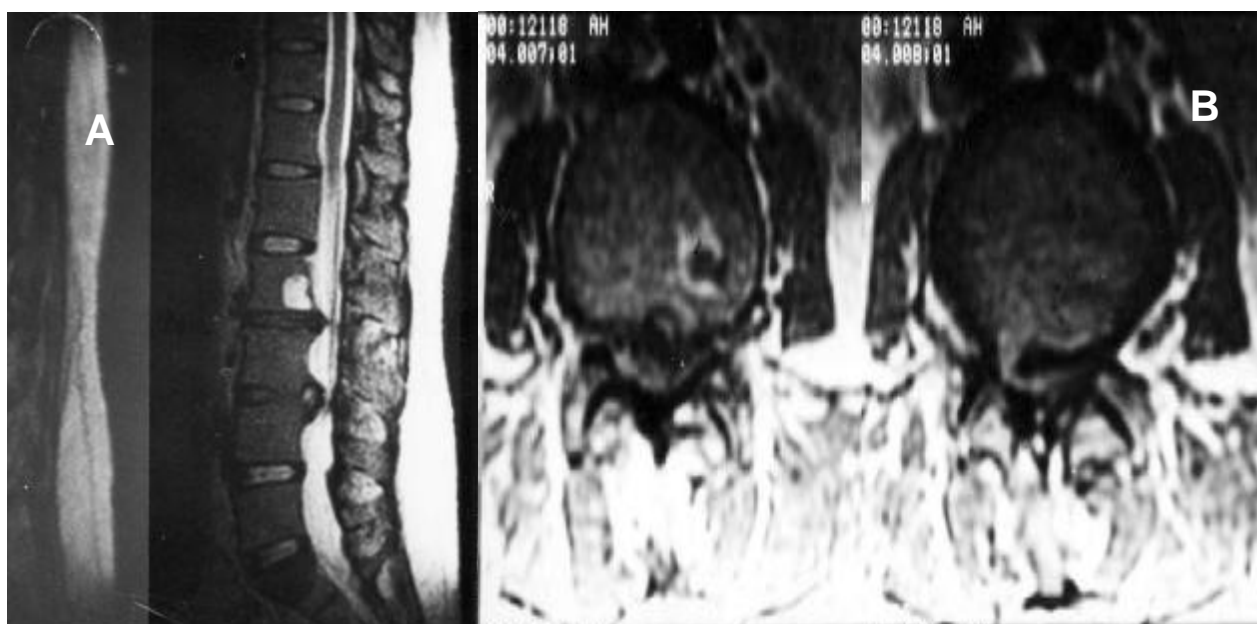


Figure 2. Magnetic resonance image of the lumbosacral spine midsagittal section. T₂-weighted image demonstrates disc herniation at L₂-L₃ and L₃-L₄, which obliterate the spinal canal (A). Axial view demonstrates spinal canal compromise at L₃-L₄ (B).

Cauda Equina Syndrome in Pregnancy

need to be transferred to a center with access to MRI to exclude or confirm the clinical diagnosis.

This case illustrates a pregnant woman with cauda equina syndrome and the consequences of delayed diagnosis of intervertebral disc herniation. A high index of suspicion is provided by appropriate neurologic examination and early specialist referral to identify patients with cauda equina syndrome and facilitate early treatment.

References

- 1 Fast A, Shapiro D, Ducommun EJ, et al. Low back pain in pregnancy. *Spine*. 1987; **12**: 368 – 71.
- 2 LaBan MM, Perrin JC, Latimer FR. Pregnancy and the herniated lumbar disc. *Arch Phys Med Rehabil*. 1983; **64**: 319 – 21.
- 3 O'Laoire SA, Crockard HA, Thomas DG. Prognosis for sphincter recovery after operation for cauda equina compression owing to lumbar disc prolapse. *Br Med J (Clin Res Ed)*. 1981; **282**: 1852 – 4.
- 4 Brown MD, Levi AD. Surgery for lumbar disc herniation during pregnancy. *Spine*. 2001; **26**: 440 – 3.
- 5 Ashkan K, Casey AT, Powell M, et al. Back pain during pregnancy and after childbirth: an unusual cause not to miss. *J R Soc Med*. 1998; **91**: 88 – 90.
- 6 Timothy J, Anthony R, Tyagi A, et al. A case of delayed diagnosis of cauda equina syndrome in pregnancy. *Aust NZ J Obstet Gynaecol*. 1999; **39**: 260 – 1.
- 7 Miller DW, Hahn JF. General methods of clinical examination. In: Youmans JR, ed. *Neurological Surgery*. 4th ed. Philadelphia: Saunders; 1996: 40.
- 8 Cunningham FG, Macdonald PC, Gant NF, et al. *Williams Obstetrics*. 20th ed. Stamford, CT: Appleton & Lange; 1997.
- 9 Evans JA, Sauitz DA, Kanal E, et al. Infertility and pregnancy outcome among magnetic resonance imaging workers. *J Occup Med*. 1993; **35**: 1191 – 5.
- 10 LaBan MM, Rapp NS, Van Oeyen P, et al. The lumbar herniated disc of pregnancy: report of six cases identified by magnetic resonance imaging. *Arch Phys Med Rehabil*. 1995; **76**: 476 – 9.
- 11 Alexander JT, McCormick PC. Pregnancy and discogenic disease of the spine. *Neurosurg Clin N Am*. 1993; **4**: 153 – 9.
- 12 Weinreb JC, Wolbarsht LB, Cohen JM, et al. Prevalence of lumbosacral intervertebral disc abnormalities on MR images in pregnant and asymptomatic nonpregnant women. *Radiology*. 1989; **170**: 125 – 8.