

CASE REPORT

SEMINAL VESICLE CYSTS: CASE REPORTS AND LITERATURE REVIEW

Seyed-Mohsen Hessami MD*, Mohammad-Hassan Hourang MD*, Alireza Rasekhi MD**,
Nader Tavakoli MD***

*Department of Urology and General Surgery, Fassa University of Medical Sciences, Fassa,

**Department of Radiology, Shiraz University of Medical Sciences, Shiraz,

***Department of Emergency Medicine, Iran University of Medical Sciences, Tehran, Iran

Seminal vesicle cysts are unusual but treatable causes of lower urinary tract symptoms. Transrectal ultrasonography is a good method for initial evaluation of seminal vesicle cysts; endorectal magnetic resonance imaging should be reserved for the cases whose ultrasonographic results are not conclusive. Treatment should be restricted to symptomatic patients. Transvesical approach and laparoscopy in the hands of an experienced urologist are the best methods for resection of seminal vesicle cysts. In this article, two cases of acquired and congenital seminal vesicle cysts are presented and the clinical symptoms, diagnosis, and management of are discussed.

Archives of Iranian Medicine, Volume 6, Number 4, 2003: 289 – 292.

Keywords • acquired • congenital • seminal vesicle cyst

Introduction

Cysts of seminal vesicle are rare.¹ Acquired cysts, due to obstruction of ejaculatory duct, are the sequelae of an inflammatory process such as prostatitis, seminal vesiculitis, and prostate surgery.² Congenital cysts are associated with ipsilateral renal agenesis or dysplasia in two-thirds of patients.²

The majority of patients are asymptomatic. Seminal vesicle cysts usually present in the second and third decades of life and are predominantly seen in white patients.² We present here, two cases of this unusual condition, and their management.

Case Reports

Case 1

A 43-year-old man was referred to the Urology Clinic complaining of pelvic discomfort for the past few months with no history of dysuria, hematuria, painful ejaculation or hematospermia.

Physical examination was unremarkable except for a soft cystic mass on the superior aspect of the prostate, found on digital rectal examination. Laboratory data including urinalysis and culture were unremarkable. Renal and bladder ultrasonography showed normal kidneys, bladder, and prostate with a seminal vesicle cyst on the left side (51 × 72 mm) which was confirmed by transrectal ultrasonography and magnetic resonance imaging (MRI) (Figure 1). Cystoscopy showed bulging of the bladder base and normal

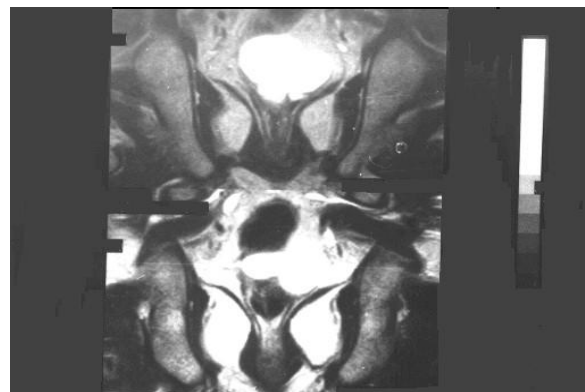

Figure 1. MRI (axial T₂-weighted image), coronal cut just posterior to the urinary bladder, reveals a large septated left seminal vesicle cyst (Case 1).

•Correspondence: S.M. Hessami MD, Department of Urology, Fassa University of Medical Sciences, Fassa, Iran.
Fax: +98-731-2227273, E-mail: sm_hesami@yahoo.com.

Seminal Vesicle Cysts

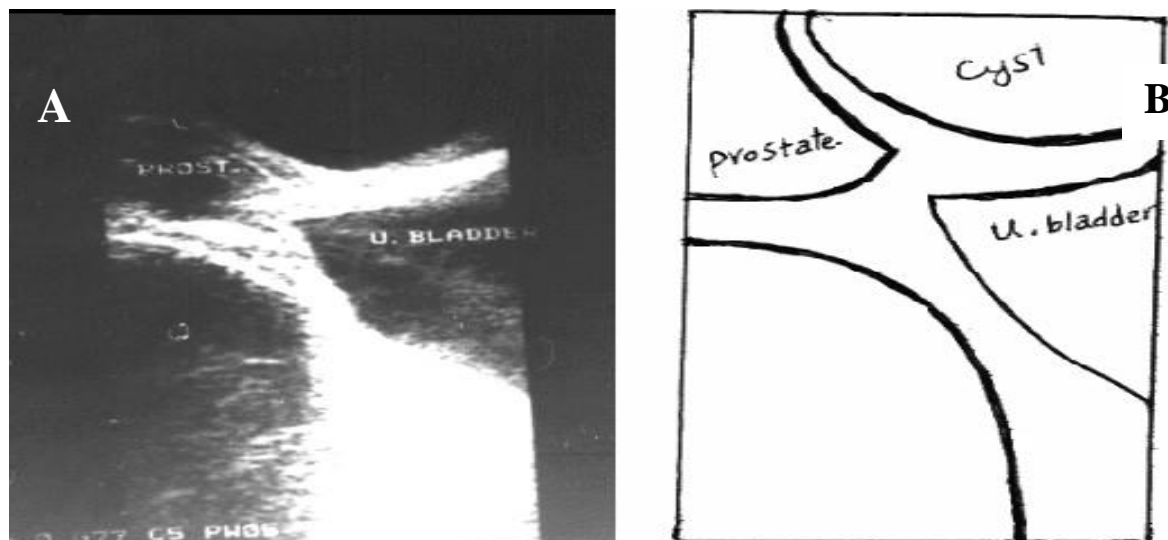


Figure 2. Case 2. Transrectal longitudinal ultrasonogram. Cystic structure in the right seminal vesicle (A). Schematic drawing (B) explaining the image in part A.

ureteral orifices.

Case 2

A 34-year-old man was presented to the Urology Clinic with repeated lower urinary tract infections and hematospermia for the past few years. Physical examination showed no abnormalities except for a soft nontender mass above the prostate on the right side, detected in rectal examination. The findings were confirmed by transrectal ultrasonography and magnetic resonance imaging (Figures 2 and 3). The right kidney was not seen in ultrasonography and intravenous pyelography (IVP).

Cystoscopy revealed bulging on the right side of the trigone with no ureteral orifice. Owing to controlled symptoms and small size of the cysts

(less than 10 cm), no surgical treatment was done for the seminal vesicle cysts in the mentioned cases.

Discussion

Case 2 is a typical case of seminal vesicle cyst with ipsilateral renal agenesis while Case 1 is a typical case with normal renal development.

Congenital or acquired seminal vesicle cysts involve less than 0.005% of the population.¹ Congenital cysts, associated with ipsilateral malformation of the upper urinary tract, were described by Zinner in 1914.^{3, 4} Seminal vesicle cysts are characteristically unilateral with no side predilection and only two cases of bilateral seminal vesicle cysts have been reported in the literature.³

They contain pale white fluid with spermatozoa and white blood cells, and are lined with cuboidal or flattened epithelium with a fibrous wall.² Congenital cysts are associated with ipsilateral renal agenesis in two-thirds of the cases.² Inferior vena cava duplication, undescended testis, ectopic ureter, and hemivertebra have been reported in association with seminal vesicle cysts.⁵

The acquired cyst is usually associated with inflammation or obstruction of ejaculatory ducts due to prostatitis, seminal vesiculitis, or prostatic surgery.²

Most of the cases are asymptomatic. The majority of seminal vesicle cysts are small (< 5 cm) and present either asymptotically or with infective or irritative urinary symptoms. Large cysts (> 8 – 10 cm) may present with symptomatic

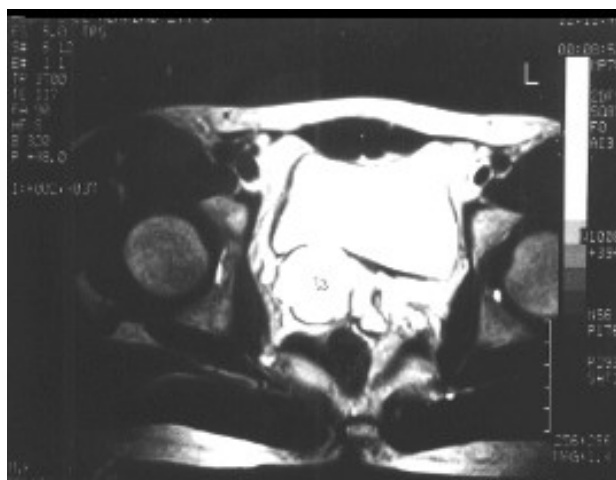


Figure 3. MRI (axial T₂-weighted image), right seminal vesicle cyst, shows the same signal as urinary bladder (Case 2).

obstruction of the bladder and/or bowel, and occur less frequently.³ The diagnosis of these malformations is established mostly at the time of the greatest sexual activity when seminal fluid accumulates in the seminal vesicle as a result of incomplete drainage. Most of the patients have signs of infection on the initial evaluation.³ Patients with seminal vesicle cysts may present with symptoms of bladder irritation, chronic recurrent prostatitis and recurrent epididymitis, painful ejaculation, urethral discharge, urgency, hesitancy, hematuria,⁶ acute urinary retention, pain on defecation, tenesmus,⁵ constipation,² pelvic discomfort, perineal pain, testicular pain,⁷ abdominal mass, pelvic mass,⁸ infertility,⁹ and hematospermia.

Imaging modalities for the diagnosis of seminal vesicle cysts are as follows:

Vasovesiculography

Vaso-vesiculography may be required to document the lesion. This can be done transrectally, transurethrally, or intraoperatively by injection through the vas. All of these procedures are invasive and the last one carries the risk of vasal obstruction.⁷ This is indicated only to differentiate the entity from other cystic malformations in the pelvis.

Transrectal ultrasonography (with needle aspiration) and computed tomography scan

These procedures detect the characteristics of the cyst and its relationship with adjacent pelvic structures.⁷ Transrectal ultrasonography is a standard method for evaluation of patients with hematospermia, azoospermia,¹⁰ and low ejaculate volume, and is a useful procedure for the diagnosis of seminal vesicle cysts.⁸

Magnetic resonance imaging (MRI)

MRI is the best noninvasive procedure for visualization of seminal vesicle cysts and surrounding organs.⁵

The resolution of prostatic and vesicular anatomy was improved when an endorectal surface-coil (a device for increasing the resolution of the image) was used. Close proximity of endorectal coil to retrovesical structures, the spatial resolution reduction of section thickness, multiplanar capability, and high soft tissue contrast makes MRI an appropriate noninvasive imaging method for the seminal tract.¹¹ Endorectal MRI should be reserved for selected patients when the

result of ultrasonography is not conclusive.¹²

Cystoscopy

Cystoscopy is a necessary procedure for documenting the hemitrigone, absence of the ureteral orifice on the involved side, and extrinsic mass effect on the bladder.¹³

Intravenous urography (IVU)

IVU is a usual procedure for detection of concomitant urinary system abnormalities.

Treatment should be considered for symptomatic cases^{5,14} and ranges from conservative medical treatment to surgical excision.¹⁴ Aspiration and injection of sclerosing agents have been used for small cysts, but recurrence and infection are disadvantages of this procedure.^{3,5}

Transurethral resection with unroofing of the cyst is a simple procedure, but the created diverticulum⁵ may predispose the patient to recurrent urinary tract infections and epididymitis.^{3,5,13,15}

Complete removal of the cyst through laparoscopy or an open procedure using either transperitoneal, transvesical, or retroperitoneal approach is the best decision. Transperineal resection of seminal vesicle cysts carries the high risk of impotence even if a nerve sparing approach is attempted.⁷ Transcoccygeal resection of cyst is accompanied by patient discomfort, rectal injury, and impotence.⁷ Retrovesical resection of seminal vesicle cysts is considered in the patients requiring bilateral excision of small seminal vesicle cysts or benign masses. Complications of this procedure include rectal injury, bladder laceration, and hemorrhage.⁷

Paravesical resection of seminal vesicle cysts is indicated when resection of a large unilateral cyst that resides lateral and superior to the bladder with nephroureterectomy is needed.⁷ Transvesical resection of seminal vesicle cysts has been described by numerous workers, with excellent exposure to anatomy and less morbidity compared with other approaches. Transvesical approach and laparoscopic excision of cysts seem to be the best methods for resection of seminal vesicle cysts.^{1,13,16}

References

- 1 Gonzalez CM, Dalton DP. Endoscopic incision of a seminal vesicle cyst. *Urology*. 1998; **51**: 831 – 2.
- 2 Razi A, Imani B. Seminal vesicle cyst presenting with lower urinary tract symptoms and huge abdominal mass. *J*

Seminal Vesicle Cysts

- Urol.* 2000; **164**: 1309 – 10.
- 3 Selli C, Bartoletti R, Travaglini F, et al. Surgical treatment of bilateral large seminal vesicle cysts associated with unilateral renoureteral agenesis. *Urol Int.* 1997; **58**: 66 – 8.
 - 4 Adeyoju AB, Taylor P, Payne SR. Congenital seminal vesicle cyst: an unusual but treatable cause of lower urinary tract/genital symptoms. *BJU Int.* 2001; **87**: 901 – 2.
 - 5 Callewaert P, De Coster M, Vuylsteke P, et al. Anal tenesmus caused by seminal vesicle cyst. *Urology.* 1997; **49**: 139 – 41.
 - 6 Kajita Y, Shimizu Y, Takao N, et al. Seminal vesicle cyst with ipsilateral renal agenesis: a case report [in Japanese]. *Hinyokika kyo.* 2001; **47**: 203 – 6.
 - 7 Surya BV, Washecka R, Glasser J, et al. Cysts of the seminal vesicles: diagnosis and management. *Br J Urol.* 1988; **62**: 491 – 3.
 - 8 Livingston L, Larsen CR. Seminal vesicle cyst with ipsilateral renal agenesis. *AJR Am J Roentgenol.* 2000; **175**: 177 – 80.
 - 9 Dominguez Dominguez M, Amaya Gutierrez J, Salazar Murillo R, et al. Cystic dysplasia in the seminal vesicle. Case report and literature review [in Spanish]. *Actas Urol Esp.* 1999; **23**: 532 – 5.
 - 10 Yassa NA, Keesara S. Role of transrectal ultrasonography in evaluating the cause of azoospermia. *Can Assoc Radiol J.* 2001; **52**: 266 – 8.
 - 11 Gruber H, Rauchenwald M, Breini E, et al. The role of endorectal surface-coil MRI in the diagnosis of ectopic insertion of the ureter into a seminal vesicle cyst. *Br J Urol.* 1996; **78**: 306 – 8.
 - 12 Engin G, Kadioglu A, Orhan I, et al. Transrectal US and endorectal MR imaging in partial and complete obstruction of the seminal duct system. A comparative study. *Acta Radiol.* 2000; **41**: 288 – 95.
 - 13 Zaontz MR, Kass EJ. Ectopic ureter opening into seminal vesicle cyst associated with ipsilateral renal agenesis. *Urology.* 1987; **29**: 523 – 5.
 - 14 Gallmetzer J, Gozzi C, Dolif R, et al. Seminal vesicle cysts (and ejaculatory duct cysts) with ipsilateral renal agenesis. Report of five cases and review of literature. *Minerva Urol Nefrol.* 1999; **51**: 27 – 31.
 - 15 van den Ouden D, Blom JH, Bangma C, et al. Diagnosis and management of seminal vesicle cysts associated with ipsilateral renal agenesis: a pooled analysis of 52 cases. *Eur Urol.* 1998; **33**: 433 – 40.
 - 16 Dahms SE, Hohenfellner M, Linn JF, et al. Retrovesical mass in men: pitfalls of differential diagnosis. *J Urol.* 1999; **161**: 1244 – 8.