

## INTRADURAL CHONDROMA: A CASE REPORT AND LITERATURE REVIEW

Mohammad Faraji,\* MD; Farah Ashrafzadeh, MD; and Humain Baharvahdat, MD

Department of Neurosurgery, Ghaem Hospital, Mashhad University of Medical Sciences  
Mashhad, Iran

---

*We describe a rare case of intradural chondroma. A 28-year-old man presented with headache and left hemiparesis. Axial brain computed tomography showed a large lobulated and calcified mass in the right frontal convexity. He was operated and the tumor was completely removed through a frontotemporal craniotomy. The tumor was totally intradural. Histopathology examination revealed hyaline lobules of mature cartilaginous tissue compatible with a chondroma.*

Keywords: *intradural; chondroma; cartilaginous tumor.*

*Arch Iranian Med. 7(1): 61 – 65; 2004*

---

### INTRODUCTION

Intracranial chondromas are rare and only representing 0.2 – 0.3% of primary intracranial tumors.<sup>1,2</sup> They usually arise from the synchondrosis at the base of skull.<sup>1-6</sup> Intradural presentation of chondroma is exceedingly rare.<sup>7-23</sup> We present a young man with intradural chondroma and review the clinical and radiological presentation of the tumor, its pathological features, and its management.

### CASE REPORT

A 28-year-old man was presented with headache and weakness of the left limbs for one month. He had no seizure. On admission, the clinical examination revealed a left mild hemiparesis. The other clinical and neurological examinations were normal.

The axial brain computed tomographic (CT) scan showed a large lobulated hyperdense mass in the right frontal area with a convexity base (Figure 1a). It contained areas of clumped calcification. The tumor did not enhance with contrast (Figure 1b). There was no edema but it had mass effect on cerebral parenchyma and frontal horn of right lateral ventricle.

A frontotemporal craniotomy was performed. The tumor was intradural with no attachment to the skull. It was easily separated from the dura matter and brain surface and was completely removed. The tumor was bluish-white, firm, and lobulated in appearance. The postoperative course was unremarkable. CT scan showed no evidence of the tumor one month after operation (Figure 2). The patient was well without neurological deficit six months after tumor removal.

Pathological evaluation revealed a 10 × 7 × 5.5 centimeter cube, bluish-white, firm, elastic lobulated mass without necrosis and cyst formation, covered by a thin transparent capsule. Histologically the lesion was made of hyaline lobules of mature cartilaginous tissue containing chondrocytes with uniform nuclei, without atypia or mitotic activity settling in lacunar spaces in the calcified vascular matrix (Figure 3).

### DISCUSSION

Intracranial chondromas are rare and benign lesions with an incidence of 0.2 – 0.3% of primary intracranial tumors.<sup>1, 2</sup> Hirshfield first described intracranial chondroma in 1851. Nixon published the first operative resection of intracranial chondroma in 1982.<sup>24</sup> We found 50 cases of intradural benign cartilaginous tumor in the literature,<sup>13-16</sup> including our patient.

About 70 – 85% of the intracranial chondromas are extradural and arise from the skull base.<sup>14-16, 20</sup>

---

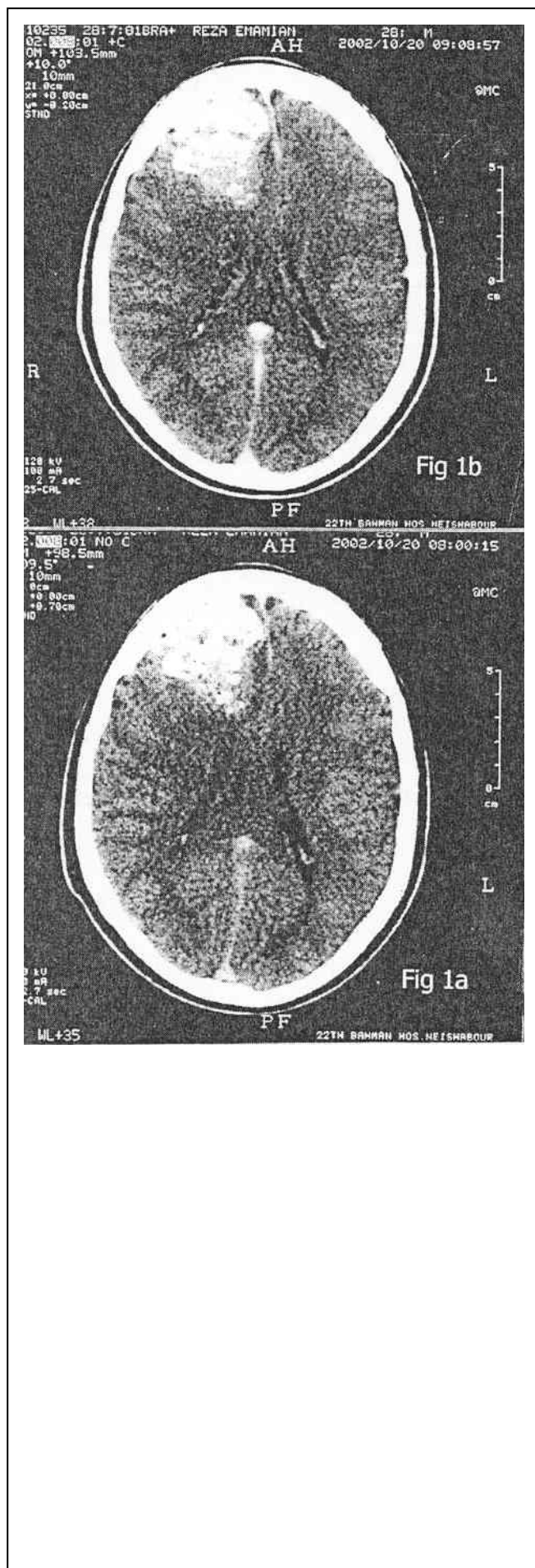
\*Corresponding author:

Mohammad Faraji, MD

# 48, Dadgar 1 Avenue, Ahmadabad Blvd,  
Mashhad, Iran

Fax: +98-511-8425878

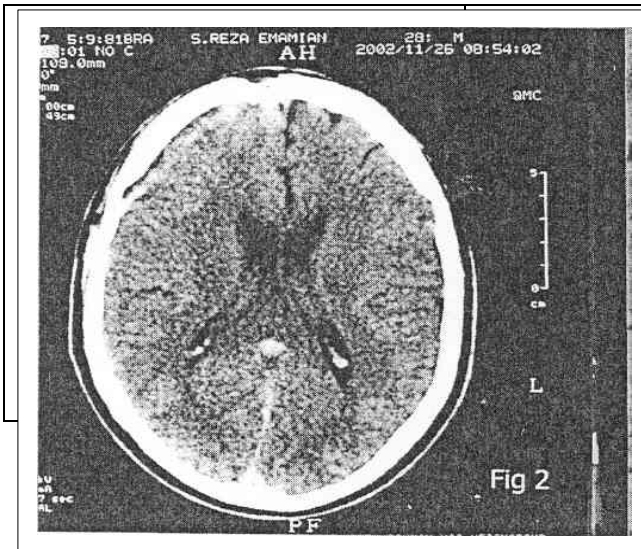
E-mail: farajirad@yahoo.com



**Figure 1.** The axial brain CT scan showed a large lobulated, calcified, hyperdense mass lesion in the right frontal area (a) which was not enhanced with contrast medium (b). No edema was visible in either of the CT scans.

Skull base chondromas were reported in association with Ollier's disease<sup>25 - 27</sup> and Maffuci's syndrome.<sup>24</sup> Malignant change was reported in an intracranial chondroma in a patient with Maffuci's syndrome.<sup>28</sup> Approximately 15 - 30% of intracranial chondromas do not arise from the skull base and are intradural.<sup>13, 15, 16, 20</sup> They were reported in the choroids plexus/intraventricular,<sup>29, 30</sup> sellar and parasellar,<sup>31,32</sup> intracerebral (pons),<sup>33</sup> and attached to the dura matter (convexity or falx) (Table 1).<sup>11, 16, 18, 20, 23</sup>

Attachment to dura, particularly over cerebral



**Figure 2.** There is no evidence of tumor in CT scan taken one month after operation.

convexities included 70% of intradural chondroma and 15% of intracranial chondroma.<sup>15</sup>

The origin of intracranial chondroma is not known for sure. Many theories have been suggested. The skull base chondromas have been believed to originate from embryonic rests of chondrogenic cells along baseline synchondrosis.<sup>1,4,6,15,26,34</sup> It is thought that intradural chondromas develop from heterotropic chondrocystes or metaplasia of other normal tissue, including meningeal fibroblasts or perivascular mesenchymal tissue.<sup>13 - 15</sup> Intracranial chondromas are usually seen in females in the 2<sup>nd</sup> to 5<sup>th</sup> decades of life.<sup>1, 35</sup> In intradural chondroma, the mean age is 29 years at presentation, with slight male predominance (63.5% versus 37.5%) (Table

may show evidence of hyperostosis of the internal table of the skull, increased intracranial pressure, and areas of calcification.<sup>16,20</sup> The convexity chondromas may have stippled, flocculent, and ring calcification.<sup>14</sup> However, falxine chondromas do not usually show calcification.<sup>20</sup> According to Lacerte et al,<sup>15</sup> the intradural chondromas have two distinct CT scan presentations. The type 1, named classical, is more common and reveals mixed density with minimal or moderate enhancement, whereas type 2 is less frequent and has a central hypodense area, which is composed of a cystic degeneration<sup>11, 14</sup> or of a very loose-texture connective tissue without necrosis in pathological evaluation.<sup>15</sup> Tanohota et al stress that enhancement of chondromas increases after 30 minutes of contrast injection.<sup>20</sup>

The MRI features have been reported in a few cases of intracranial chondromas. The tumor shows heterogenous signal intensity with more hypodense on T1 spin echo scan and iso- to hyper-intense on

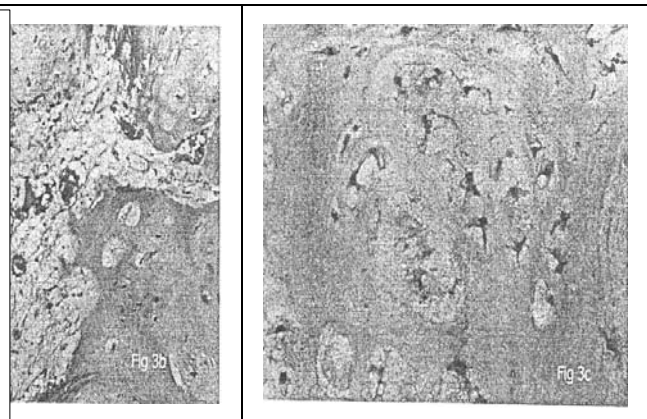


Fig 3. a) capsule with lobules of mature cartilaginous tissue (H and E × 10). b) lobules of cartilaginous tissue (H and E × 10). c) The mature chondrocytes settled in the lacunae (H and E × 20).

2). Because of the noninvasive and slow-growing nature of intradural chondromas the patients often present with a long-standing history of headache and symptoms of increased intracranial pressure. Patients may have signs and symptoms related to compression of adjacent structure, like seizure, personality changes, and hemiparesis.<sup>14, 15, 20</sup> Despite paucity of symptoms, the intracranial chondroma are usually very large (mean diameter, 6 cm and mean weight, 170 grams) at diagnosis which may be explained by their slow-growing nature and their common location in frontoparietal area,<sup>15</sup> therefore as part of a work-up for other reasons.<sup>14</sup>

The radiological appearance of intradural chondromas is fairly typical. On skull X-ray, chondromas, particularly over cerebral convexities,

T2 spin echo scan. The tumor enhances minimally to moderately following administration of contrast.<sup>15</sup> In type 2, the T2 spin echo scan shows a peripheral heterogenous hypointense area and a well-demarcated hyperintense central area.<sup>14, 15</sup> The former may enhance with contrast and show ring

**Table 1.** Reported location of intradural chondroma.\*

Location	No. of cases (%)
Menings	37 (74 %)
Convexity	22 (44 %)
1. Frontoparietal	20 (40 %)
2. Others	2 (4 %)
Falx	15 (30 %)
Intracerebral	7 (14 %)
Choroid plexus / intraventricular	6 (12 %)
Total	50 (100 %)

\* Based on references 16, 19, and 21.

enhancement on T1 spin echo scan.<sup>9, 14, 15, 18</sup> The latter did not enhance with contrast<sup>13</sup> and its signal intensity in T2 spin echo scan may be explained

with a very loose-texture edematous connective

<b>Age at presentation:</b>	range, 5 – 64; mean, 29 years*
<b>Sex:</b> *	male to female ratio, 1.7/1; female, 15; male, 25
<b>Duration of symptoms:</b>	mean, 37; range, 0.5 – 10 months*
<b>Tumor size:</b>	maximal diameter, mean, 6.1; range, 1.5 – 10 centimeters †
<b>Tumor weight:</b>	mean, 170; range, 67 – 250 grams ‡

tissue described by Lacerte et al.<sup>15</sup> MRI scan is capable of distinguishing between the tumor and gray-matter, confirming the extraaxial location of the tumor.<sup>14</sup> There is no perilesional edema.<sup>14,15</sup> On angiography, the chondromas present as an avascular extraaxial mass.<sup>11, 15 – 17, 30, 35 – 37</sup>

The differential diagnosis of intradural chondroma, particularly the convexity ones, are meningioma and chondrosarcoma. However, the clinical presentation of intradural chondromas is similar to meningiomas, but they differ from meningiomas in radiological appearance. In contrast to chondromas, 90% of meningiomas enhance uniformly and strongly on both CT scan and MRI. Perilesional edema is present in 60% of meningiomas. On angiography the majority of convexity meningiomas are vascular masses and show a sunburst pattern.<sup>38</sup> In the literature the cartilaginous variant of meningioma has been described on histopathological evaluation.<sup>5,39</sup> The presence of foci of cells with meningotheial features help to diagnose meningiomas.<sup>39</sup>

Chondrosarcomas have a variable clinical course with frequent recurrence and occasional metastasis.<sup>15</sup> Chondrosarcomas are usually hypo-to isointense on T1 spin echo scan and hyperintense on T2 spin echo scan. Strong but heterogenous enhancement of chondrosarcoma following contrast administration may distinguish these tumors from chondromas.<sup>38</sup> On histopathological evaluation, when binucleated cells and nuclear pleomorphism are evident within the chondroma specimens a diagnosis of low grade (grade I) chondrosarcoma needs to be considered.<sup>39</sup> In addition, any

**Table 2.** General features of reported intradural chondroma.  
\*The data were available for 40 patients; †38 patients; ‡37 patients; Based on references 16, 19, and 21.

chondrosarcoma can contain areas of very well differentiated chondroid tissues and this stresses the need for extensive and meticulous examination of the pathological specimens of the tumor before definite diagnosis of benign chondroma is reported.<sup>15</sup>

Surgical resection is the treatment of choice for intradural chondromas.<sup>14-16</sup> Total resection of tumor is usually possible, particularly in convexity chondroma, because they are well-demarcated without parenchymal invasion and easily accessible on surgery. Its recurrence is rare after total tumor removal. If a benign, diagnosed chondroma shows rapid recurrence, invasion, or metastasis, chondrosarcomas should be suspected and the previous specimen should be reviewed for correct diagnosis.<sup>15</sup> We conclude that intradural chondromas are very rare and benign cartilaginous tumors. They present in young adults with slight male predominance. Because of their slow-growing nature, the clinical symptoms and signs are not prominent. They can be suggested according to their appearance in imaging studies. The treatment of choice is total resection of the tumor, which is usually possible. The chondromas can be distinguished easily from its malignant counterpart, chondrosarcoma, on the histopathological evaluation.

## REFERENCES

1. Berkman YM, Blatt ES. Cranial and intracranial cartilaginous tumors. *Clin Radiol.* 1968; 19: 327 – 33.
2. Zulch KJ, Wechsler W. Pathology and classification of gliomas. *Pro Neurol Surg.* 1968; 2: 1 – 84.
3. Gabrielsen TO, Kingman AF. Osteocartilaginous tumors of the base of the skull. Report of a unique case and review of the literature. *Am J Roentgenol Radium Ther Nucl Med.* 1964; 91: 1016 – 23.
4. Minagi H, Newton TH. Cartilaginous tumors of the base of skull. *Am J Roentgenol Radium Ther Nucl Med.* 1969; 105: 308 – 13.
5. Russell DS, Rubinstein LJ. *Pathology of Tumors of the Nervous System.* 5th ed. London: E. Arnold; 1989.
6. Sarwar M, Swischuk LE, Schechter MM. Intracranial chondroma. *Am J Roentgenol.* 1976; 127: 973 – 7.
7. Acampora S, Troisi F, Fusco G, DelGaizo S. Voluminous intracranial chondroma. *Surg Neurol.* 1982; 18: 254 – 7.
8. Alpers BJ. Cerebral osteochondroma of dural origin. *Ann Surg.* 1935; 101: 27 – 37.
9. Beck DW, Dyste GN. Intracranial osteochondroma: MR and CT appearance. *AJNR Am J Neuroradiol.* 1989; 10 (5 suppl): S7 – 8.
10. Burger PC, Scheithauer BW, Vogel FS. *Surgical Pathology of the Nervous System and its Coverings.* 3rd ed. New York: Churchill Livingstone; 1991: 96 – 116.
11. Hadadian K, Abtahii H, Asil ZT, Rakhshan M, Vessal P. Cystic falicine chondroma: case report and review of the literature. *Neurosurgery.* 1991. 29: 909 – 12.
12. Hardy RW, Benjamin SP, Gardner WJ. Prolonged survival following excision of dural chondroma. *J Neurosurgery.* 1978; 48: 125 – 7.

13. Holthouse DJ, Robbins PD, Knuckey NK. Solitary intradural fibrochondroma in a 16-year-old boy. *J Clin Neurosci*. 1999; 6: 355 – 7.
14. Khosrovi H, Sadrolhefazi A, el-Kadi H, Bloomfield SM, Scochet SS. Intradural convexity chondroma: a case report and review of diagnostic features. *W V Med J*. 2000; 96: 612 – 6.
15. Lacerte D, Gagne F, Copty M. Intracranial chondroma: report of two cases and review of the literature. *Can J Neurol Sci*. 1996; 23: 132 – 7.
16. Mapstone TB, Wongmongkolrit T, Roessman U, Ratcheson RA. Intradural chondroma: a case report and review of the literature. *Neurosurgery*. 1983; 12: 111 – 4.
17. Matz S, Israeli Y, Shlit MN, Cohen ML. Computed tomography in intracranial supratentorial osteochondroma. *J Comput Assist Tomogr*. 1981; 5: 109 – 15.
18. Nakazawa T, Inoue T, Suzuki F, Nakasu S, Handa J. Solitary intracranial chondroma of the convexity dura: case report. *Surg Neurol*. 1993; 40: 495 – 8.
19. Ozgen T, Pamir MN, Akalan N, Bertan V, Onol B. Intracranial solitary chondroma. Case report. *J Neurosurg*. 1984; 61: 399 – 401.
20. Sebbag M, Schmidt V, Leboucq N, Bitoun J, Castan PH, Frerebeau PH. Chondrome dure-mérien; a propos d'un cas et revue de la littérature [in French]. *J Radiol*. 1990. 71: 495 – 8.
21. Siris JH, Angrist A. Chondroblastic meningioma. *Am J Surg*. 1942; 57: 162 – 7.
22. Wu WQ, Lapi A. Primary nonskeletal intracranial cartilaginous neoplasms: report of chondroma and a mesenchymal chondrosarcoma. *J Neurol Neurosurg Psychiatry*. 1970; 33: 469 – 75.
23. Yang PJ, Seeger JF, Carmody RF, Fleischer AS. Chondroma of falx: CT findings. *J Comput Assist Tomogr*. 1986; 10: 1075 – 6.
24. Chakraborty S, Tamaki N, Kondoh T, Kojima N, Kamikawa H, Matsumoto S. Maffucci's syndrome associated with intracranial enchondroma and aneurysm: case report. *Surg Neurol*. 1991; 36: 216 – 20.
25. Dany A, Vidal J, Dumas M, Ravon R, Bokor J. Cerebellopontine angle chondroma. A report of one personal case (author's transl) [in French]. *Neurochirurgie*. 1980; 26: 355 – 7.
26. Dutton J. Intracranial solitary chondroma. Case report. *J Neurosurg*. 1978; 49: 460 – 3.
27. Traflet RF, Babaria AR, Barolat G, Doan HT, Gonzalez C, Mishkin MM. Intracranial chondroma in a patient with Ollier's disease. *J Neurosurg*. 1989; 70: 274 – 6.
28. Bushe KA, Naumann M, Warmuth-Metz MM, Meixensberger J, Muller J. Maffucci's syndrome with bilateral cartilaginous tumors of cerebellopontine angle. *Neurosurgery*. 1990; 27: 625 – 8.
29. Salazar J, Vaquero J, Aranda IF, Menendez J, Jimenez MD, Bravo G. Choroid plexus papilloma with chondroma: case report. *Neurosurgery*. 1986; 18: 781 – 3.
30. Valdueza JM, Freckmann N, Herrmann HD. Chondromatosis of the choroid plexus: case report. *Neurosurgery*. 1990; 27: 291 – 4.
31. Furui T, Iwata K, Yamamoto H, Murakami A. A case of intracranial chondroma presenting with hemorrhage [in Japanese]. *No Shinkei Geka*. 1990; 18: 543 – 6.

32. Munemitsu H, Matsuda M, Hirai O, Fukumitsu T, Kanamura J. Intrasellar chondroma. *Neurol Med Chir (Tokyo)*. 1981; 21: 775 – 80.
33. Ishii R, Sato S, Ueki K, Oyake Y. Myxoosteochondroma in the pons. Case report. *J Neurosurg*. 1974; 41: 240 – 3.
34. List CF. Osteochondroma arising from the base of the skull. *Surg Gynecol Obstet*. 1943; 76: 480 – 92.
35. Doran SE, Gebarski SS, Hoff JT. Tumors of skull. In: Youmans JR, ed. *Neurological Surgery: A comprehensive Reference Guide to the Diagnosis and Management of Neurosurgical Problems*. 4th ed. Vol 3. Philadelphia: WB Saunders; 1996: 2998 – 3023.
36. Ahyai A, Spoerri O. Intracerebral chondroma. *Surg Neurol*. 1979; 11: 431 – 3.
37. Kretzschmar HA, Eggert HR, Beck U, Furmaier R. Intracranial chondroma: case report. *Surg Neurol*. 1989; 32: 121 – 5.
38. Osburn AG. *Diagnostic Neuroradiology*. St Louis: Mosby; 1994.
39. McKeiver PE, Blairas M, Nelson JS. Tumors: application of light microscopic methods. In: Gracia JH, ed. *Neuropathology, the Diagnostic Approach*. St Louis: Mosby; 1997: 97 – 192.

