

## A CASE REPORT OF COLON AND RECTUM OBSTRUCTION BECAUSE OF SAND IN A THREE-YEAR-OLD BOY

Abdolhadi Jahanshahee, MD; Mohammad Hassan Pipelzadeh, PhD,\* and Mojtaba Ahmadinejad, MD

Department of Pharmacology, Ahwaz University of Medical Sciences, Ahwaz, Iran

*Obstruction of the small and large intestines is a serious and life-threatening condition that requires prompt attention. Sometimes, a swallowed foreign body passes through esophagus, stomach, small intestine and eventually is compacted in colon and/or rectum. In this report, we present a case of a three-year old boy with colon obstruction due to swallowing sand. Finger manipulation proved aiding evacuation and initiation of normal bowel function.*

Keywords: *colon; rectum; obstruction; sand.*

*Arch Iranian Med. 7(1): 66 – 67; 2004*

cephazolin, 250 mg, every 6 hours. This procedure facilitated evacuation of the sand and stones. On the third day (Figure 1B), the patient had normal defecation. On the fourth day, IV infusion and antibiotic were discontinued and he was put on liquid diet. On the seventh day of admission, all the sand particles were evacuated from the colon (Figure 1C) and the patient was discharged and referred to a pediatrician for treatment of his anemia.

### CASE REPORT

A three-year-old boy from a low income farming family living in the suburbs of Ahwaz was admitted to the Accident and Emergency Department of Golestan Hospital. Except for the abdominal pain and distention, he had no history of mental or psychological problems. He had no fever or vomiting. Rectal examination revealed the rectum to be full of sand and small (2 – 5 mm) stones. Plain X-ray investigation found the whole colon filled with opaque foreign bodies mimicking a barium enema (Figure 1A). Laboratory tests were normal except for low hemoglobin level (7.66 g/dL), and hypochromic microcytic anemia.

Treatment initiated with stimulation and evacuation by finger manipulation, and maintained for 3 minutes daily, using lubricating jelly. The patient was put on nothing by mouth (NPO) order, and IV dextrose/saline (D/S) infusion and

### DISCUSSION

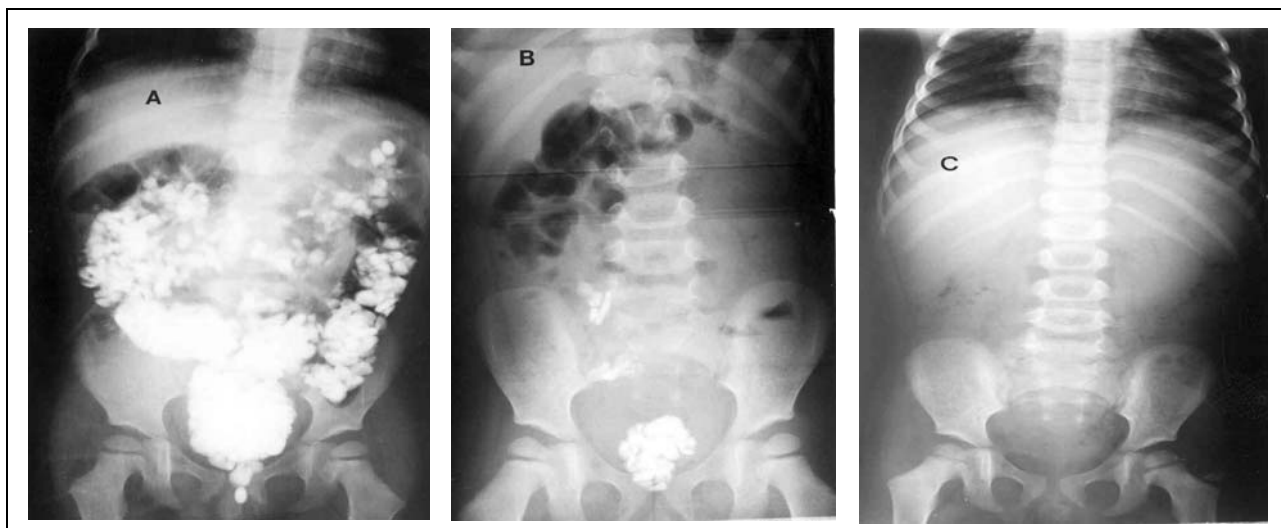
Six percent of all intestinal obstructions are related to colon.<sup>1</sup> Ninety percent of obstructions in colon are due to primary and secondary malignancies.<sup>2</sup> Benign causes of obstruction of the large bowel are fecal impaction, diverticulitis, volvulus, pancreatitis, radiotherapy, endometriosis, inflammatory bowel disease and adhesion.<sup>3 - 7</sup> Foreign bodies sometimes can cause large bowel obstruction and are primarily caused by deliberate or accidental insertion of foreign bodies via the rectum.<sup>8</sup> However, cases of obstruction in colon and rectum attributed to swallowing of solid objects have been documented.<sup>9</sup>

The major signs and symptoms of intestinal obstruction can include abdominal pain, distention, vomiting and absence of defecation and flatus. Colon obstruction has more gradual development and has milder painful episodes than those of small intestine obstruction. In all of bowel obstructions, rectal examination is important, and is diagnostic in rectal obstruction specially when foreign bodies<sup>9</sup> are involved.

In this study, a three-year-old boy had swallowed small quantities of sand over a prolonged time. This was evident from the anemic state of the patient.

\*Corresponding author:

Mohammad Hassan Pipelzadeh, PhD  
Department of Pharmacology  
Ahwaz University of Medical Sciences, Ahwaz, Iran  
Fax: +98-611-3361544  
E-mail: mhpipelzadeh@yahoo.com



**Figure 1.** Photographic illustrations of X-ray images on days 1(A), 3 (B) and 7 (C) of admission taken from a 3-year-old child with colon and rectum obstruction due to sand.

Gradual accumulation of the swallowed sand in the rectum and colon resulted in large bowel obstruction. Careful examination of the anus and use of simple plain X-ray investigation<sup>10</sup> were helpful in the diagnosis of this patient. In addition, prompt evacuation, using finger manipulation, was found useful in aiding evacuation, and initiation of normal bowel function within three days and complete evacuation of the sand particles within 7 days of treatment. This simple procedure was found easy to apply and obliterated the need for further surgical interventions. Therefore, the use of such a simple technique was found to produce favorable outcome in this emergency case. However, careful and supervised evacuation of foreign bodies is essential in order to prevent hemorrhage and perforation.

## REFERENCES

1. Sinanan MN, Pellegrini CA. Large bowel obstruction. In: Maingot R, Zinner M, Schwartz SI, Ellis H, eds. *Maingot's Abdominal Operations*. 10th ed. Stanford, CT: Appleton and Lange; 1997: 1391 – 413.
2. Welch JP, Donaldson GA. Management of severe obstruction of the large bowel due to malignant disease. *Am J Surg*. 1974; 127: 492 – 9.
3. Buechter KJ, Boustany C, Caillouette R, Cohn JI. Surgical management of the acutely obstructed colon. A review of 127 cases. *Am J Surg*. 1988; 156: 163 – 8.
4. Jones IT, Fazio VW. Colonic volvulus. Etiology and management. *Dig Dis*. 1989; 7: 203 – 9.
5. Hudson DA, de Beer JD. Acute large bowel obstruction complicating acute pancreatitis. *South Med J*. 1988; 81: 804 – 5.
6. Graham B, Mazier WP. Diagnosis and management of endometriosis of the colon and rectum. *Dis Colon Rectum*. 1988; 31: 952 – 6.
7. Farmer KC, Phillips RK. True and false large bowel obstruction. *Bailliers Clin Gastroenterol*. 1991; 5: 563 – 87.
8. Munter DW. Foreign bodies, rectum. June 29, 2001. Available from: URL: <http://www.emedicine.com/emerg/topic933.htm>.
9. Busch DB, Starling JR. Rectal foreign bodies: case reports and a comprehensive review of the world's literature. *Surgery*. 1986; 100: 512 – 9.
10. Levine MS. Plain film diagnosis of the acute abdomen. *Emerg Med Clin North Am*. 1985; 3: 541 – 62.

■ ■