
Case Report

Extramedullary Plasmacytoma of the Gingiva

Mohammad Moshref DMD*, Fatemeh Mashhadi-Abbass DMD*, Soodabeh Sargolzaei DMD*,
Shima Nafarzadeh DMD*

Extramedullary plasmacytoma is defined as neoplastic proliferation of plasma cells in soft tissue. It accounts for up to 3% of all plasma cell tumors. Approximately, 90% of extramedullary plasmacytomas are found in the head and neck region commonly affecting the nasal cavity, paranasal sinuses, tonsillar fossa, and oral cavity. Radiotherapy is the common modality of treatment with or without adjuvant chemotherapy. We report a case of extramedullary plasmacytoma of the gingiva.

Archives of Iranian Medicine, Volume 10, Number 1, 2007: 91 – 93.

Keywords: Extramedullary • gingiva • plasmacytoma

Introduction

Plasmacytoma is a malignant disease.¹ It accounts for approximately 1 – 2% of human malignancies and occurs at a rate of about 3.5/100,000 per year.^{2 - 4} Plasmacytoma may present as one of the three distinct clinical entities: multiple myeloma (MM), solitary plasmacytoma of bone (SPB), and extramedullary plasmacytoma (EMP).^{5 - 7}

EMP is defined as neoplastic proliferation of plasma cells in soft tissue.^{5, 8, 9} It accounts for up to 3% of all plasma cell tumors. These tumors are four times more common in men, in their sixth to eighth decades of life.¹⁰ Approximately, 90% of EMPs are found in the head and neck region commonly affecting the nasal cavity, paranasal sinuses, tonsillar fossa, and oral cavity.^{10, 11} The etiology of this disease is unknown, but chronic stimulation, overdose irradiation, viruses, and gene interactions in the reticuloendothelial system have been suggested as etiologic factors.⁵

Martinella and Rulli, Webb et al, and Boozer et al reported cases of EMPs in the gingiva, tongue base, and soft palate.^{12 - 14}

We report a case of EMP of the gingiva in the area of upper left maxillary canine.

Case Report

A 54-year-old man came to Dr. Moshref's Clinic in January of 2003 with the chief complaint of a mass in his mouth. He had noticed the mass 2 months earlier.

On physical examination, we observed a purple nodule in the vestibular area of left maxillary canine, similar to a peripheral giant cell granuloma, measuring about 6×4×3 cm. It had a polypoid surface and had filled the whole vestibular gutter of upper left canine. The tooth was completely mobile.

Radiographic examinations revealed cortical perforation, suggestive of a malignancy. Incisional biopsy was performed for him. The mass was friable and hemorrhagic. Biopsy was done from the surface mucosa and the deep lesion. Histopathologic features showed oral mucosa lined by nonkeratinizing stratified squamous epithelium. Areas of ulceration were seen. The underlying connective tissue was infiltrated by closely packed plasma cells arranged in sheets and islands with varying degrees of differentiation, some with perinuclear halo, occasionally 2 nuclei within a single cell. Russell bodies were seen. Our diagnosis was plasmacytoma (Figure 1).

Authors' affiliation: *Department of Oral and Maxillofacial Pathology, Shaheed Beheshti Dental School, Tehran, Iran.

Corresponding author and reprints: Shima Nafarzadeh DMD, Department of Oral and Maxillofacial Pathology, Shaheed Baheshi University of Medical Sciences, Tehran, Iran.

Fax: +98-212-240-3194, E-mail: shima_nafar2004@yahoo.com.

Accepted for publication: 30 August 2006

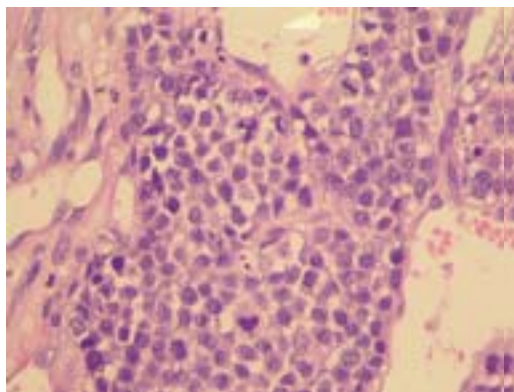


Figure 1. Pathologic specimen shows dysplastic plasmacytoma with vesiculated and hyperchromatic nuclei and mitotic activity (H&E; original magnification $\times 40$).

His bone marrow biopsy was negative for malignancy and laboratory tests did not show anemia, hypercalcemia, or renal failure. Immunohistochemical study was carried out. Tumor cells were negative for LCA, CD3, CD20, CD45RO, CK, and Desmin. But they were rarely positive for CD138, CD38, and CD79. Ki-67 was positive in all tumoral cells. The immunohistochemical study was also consistent with plasmacytoma.

The patient received field radiotherapy to his gingiva (40 GY in 4 weeks) and was asymptomatic for more than 11 months.

Discussion

Multiple myeloma is a systemic disease and is characterized by neoplastic proliferation of monoclonal immunoglobulins (M protein). It is a disseminated disease involving many bones.¹⁵

The incidence of the MM is below 1% of all malignancies and 10% of all hematologic neoplasms. Solitary plasmacytoma is seen in 5 – 10% of all plasmacytoma cases. It can be classified into SPB and EMP. Plasmacytoma of bone is twice as common as extramedullary type.¹⁵

Clinical manifestations of plasmacytoma of the oral cavity consist of jaw pain, tooth pain, paresthesia, swelling, tissue mass, mobility of teeth, migration of teeth, hemorrhage, and pathologic fracture of the involved bone.^{5, 15, 16}

According to Miller, EMP of the oral cavity can show a cauliflower growth.¹⁷ Solitary plasmacytoma differs from MM by lack of plasma cell infiltration in a random bone marrow biopsy.

The affected patients may show no signs of anemia, hypercalcemia, or renal failure either.¹¹ Majumdar et al reported that 15 – 38% of EMPs can express amyloid and IgG is the commonest immunoglobulin, which may be expressed by tumor cells.¹⁰

On radiographs, EMP can erode bone making it difficult to be distinguished from SPB.¹⁰

Histopathologic features of EMP show a connective tissue greatly infiltrated by plasma cells which are like focal sheets, small islands, or plasmacytoid nodules.^{1, 5}

The treatment of choice for EMP is radiotherapy because the disease is highly radiosensitive.^{10, 18} Some reports have described long-term control following radiotherapy of the solitary lesion with a high likelihood of cure.^{3, 19, 20} Mendenhall et al²¹ have reported 94% local control rate in solitary plasmacytoma with doses exceeding 40 GY in four weeks while some other researchers have shown less favorable results.^{18, 22} Adjuvant chemotherapy is sometimes indicated in an attempt to delay the conversion of the disease to myeloma.^{2, 10} Surgical excision of the tumor is not a common practice.¹⁰

The conversion rate of EMP to MM is 15 – 20%. The conversion rate of EMP to SPB is 48% and is associated with a poorer prognosis.¹⁰ Harwood et al reported the increased rate of conversion to MM if the EMP involved the adjacent bone.²³

Local recurrence has been reported to be up to 10%.¹⁰ Dissemination of the tumor takes place in 35 – 50% of EMPs.²⁴

The differential diagnoses of EMP are plasma cell granuloma, pseudolymphoma, and reactive plasmacytic hyperplasia.^{25 – 27} It is generally accepted that lesions consisting of monoclonal plasma cells are neoplastic, whereas lesions with multiclonal plasma cells are inflammatory.²⁸

Majumdar et al¹⁰ in 2002 reported two cases of EMP of paranasal sinuses and soft palate. Similar to our case, the patient who had soft palate lesion was a man and had no symptoms. But the patient with affected paranasal sinus was a female and complained of gradual loss of vision and protrusion of her right eye.

Martinelli and Rulli¹² in 1968 reported a case of EMP of the gingiva. Their patient had pain and gingivitis for about one year. Our case was found accidentally and had no symptoms except a mass for about 2 months.

References

- 1 Liebross RH, Ha CS, Cox JD, Weber D, Delasalle K, Alexanian R. Clinical course of solitary extramedullary plasmacytoma. *Radiother Oncol.* 1999; **52**: 245 – 249.
- 2 Mendenhall WM, Mendenhall CM, Mendenhall NP. Solitary plasmacytoma of bone and soft tissues. *Am J Otolaryngol.* 2003; **24**: 395 – 399.
- 3 Bolek TW, Marcus RB, Mendenhall NP. Solitary plasmacytoma of bone and soft tissue. *Int J Radiat Oncol Biol Phys.* 1996; **36**: 329 – 333.
- 4 Nofsinger YC, Mirza N, Rowan PT, Lanza D, Weinstein G. Head and neck manifestations of plasma cell neoplasms. *Laryngoscope.* 1997; **107**: 741 – 746.
- 5 Pisano JJ, Coupland R, Chen SY, Miller AS. Plasmacytoma of the oral cavity and jaws: a clinicopathologic study of 13 cases. *Oral Surg Oral Med Oral Pathol Oral Radiol Endod.* 1997; **83**: 265 – 271.
- 6 Wingo PA, Tong T, Bolden S. Cancer statistics, 1995. *CA Cancer J Clin.* 1995; **45**: 8 – 30. Erratum in: *CA Cancer J Clin.* 1995; **45**: 127 – 128.
- 7 Batsakis JG. Plasma cell tumors of the head and neck. *Ann Otol Rhinol Laryngol.* 1983; **92**: 311 – 313.
- 8 Shih LY, Dunn P, Leung WM, Chen WJ, Wang PN. Localized plasmacytomas in Taiwan: comparison between extramedullary plasmacytoma and solitary plasmacytoma of bone. *Br J Cancer.* 1995; **71**: 128 – 133.
- 9 Holland J, Trenkner DA, Wasserman TH, Fineberg B. Plasmacytoma. Treatment results and conversion to myeloma. *Cancer.* 1992; **69**: 1513 – 1517.
- 10 Majumdar S, Raghavan U, Jones NS. Solitary plasmacytoma and extramedullary plasmacytoma of the paranasal sinuses and soft palate. *J Laryngol Otol.* 2002; **116**: 962 – 965.
- 11 Neville BW, Damm DD, Allen CM. *Oral and Maxillofacial Pathology.* Philadelphia: Saunders; 2002: 527 – 528.
- 12 Martinelli C, Rulli MA. Primary plasmacytoma of soft tissue (gingiva). Report of a case. *Oral Surg Oral Med Oral Pathol.* 1968; **25**: 607 – 609.
- 13 Webb CJ, Makura ZG, Jackson SR, Helliwell T. Primary extramedullary plasmacytoma of the tongue base. Case report and review of the literature. *ORL J Otorhinolaryngol Relat Spec.* 2002; **64**: 278 – 280.
- 14 Boozer TW, Wheeler WE, Madan E. Extramedullary plasmacytoma of the soft palate. *W V Med J.* 1991; **87**: 403 – 404.
- 15 Ozdemir R, Kayiran O, Oruc M, Karaaslan O, Kocer U, Ogun D. Plasmacytoma of the hard palate. *J Craniofac Surg.* 2005; **16**: 164 – 169.
- 16 Epstein JB, Voss NJ, Stevenson-Moore P. Maxillofacial manifestations of multiple myeloma. An unusual case and review of the literature. *Oral Surg Oral Med Oral Pathol.* 1984; **57**: 267 – 271.
- 17 Miller SC. *Oral Diagnosis and Treatment.* 3rd ed. Torino: McGraw-Hill Book Company; 1957.
- 18 Kapadia SB, Desai U, Cheng VS. Extramedullary plasmacytoma of the head and neck. A clinicopathologic study of 20 cases. *Medicine (Baltimore).* 1982; **61**: 317 – 329.
- 19 Bush SE, Goffinet DR, Bagshaw MA. Extramedullary plasmacytoma of the head and neck. *Radiology.* 1981; **140**: 801 – 805.
- 20 Fletcher GH, Goepfert H. Larynx and pyriform sinus. In: Fletcher GH, ed. *Textbook of Radiotherapy.* 3rd ed. Philadelphia: Lea and Febiger; 1980: 286 – 329.
- 21 Mendenhall WM, Mendenhall CM, Mendenhall NP. Solitary plasmacytoma of bone and soft tissues. *Am J Otolaryngol.* 2003; **24**: 395 – 399.
- 22 Wiltshaw E. The natural history of extramedullary plasmacytoma and its relation to solitary myeloma of bone and myelomatosis. *Medicine (Baltimore).* 1976; **55**: 217 – 238.
- 23 Harwood AR, Dancuart F, Fitzpatrick PJ, Brown T. Radiotherapy in nonlentiginous melanoma of the head and neck. *Cancer.* 1981; **48**: 2599 – 2605.
- 24 Wanebo H, Geller W, Gerold F. Extramedullary plasmacytoma of upper respiratory tract. Recurrence after latency of thirty-six years. *N Y State J Med.* 1966; **66**: 1110 – 1113.
- 25 Bahadori M, Liebow AA. Plasma cell granuloma of the lung. *Cancer.* 1973; **31**: 191 – 208.
- 26 Holck S. Plasma cell granuloma of the thyroid. *Cancer.* 1981; **48**: 830 – 832.
- 27 Kelly AG, Rosas-Urbe A, Kraus ST. Orbital lymphomas and pseudolymphomas: a clinicopathologic study of eleven cases. *Am J Clin Pathol.* 1977; **68**: 377 – 386.
- 28 Wood NK, Goaz PW. *Differential Diagnosis of Oral and Maxillofacial Lesions.* St. Louis: The CV Mosby Co.; 1996: 385.