
Case Report

Pigmented Bowen's Disease of the Finger Mimicking Malignant Melanoma

Alireza Firooz MD*, Nader Farsi MD**, Mehdi Rashighi-Firoozabadi MD*,
Farzam Gorouhi MD*

Pigmented Bowen's disease is an uncommon *in situ* squamous cell carcinoma of the skin, which has been rarely reported on the finger. Herein, we report an unusual case of pigmented Bowen's disease of the pulp of the fourth finger in a 20-year-old white woman, which was clinically presented as a superficial, spreading malignant melanoma. Physical examination revealed a solitary hyperpigmented patch, measuring 1 cm in its greatest diameter. The lesion had an irregular, but well-defined margin, and was homogeneously brown with a smooth surface. There was no nodularity or induration in the lesion or in its surrounding skin. A skin biopsy was obtained with the clinical suspicion of malignant melanoma. Histological examination was compatible with the diagnosis of pigmented Bowen's disease. Surgical treatment was then considered and the patient underwent complete excision of the lesion. In spite of its rarity, Bowen's disease should be considered in the differential diagnosis of pigmented lesions, particularly malignant melanoma.

Archives of Iranian Medicine, Volume 10, Number 2, 2007: 255 – 257.

Keywords: Bowen's disease • malignant melanoma • pigmentation • squamous cell carcinoma

Introduction

Bowen's disease (BD) is an *in situ* squamous cell carcinoma of the skin and mucous membranes. The disease occurs with an equal incidence in both sexes and most commonly in elderly.¹⁻⁵ It usually presents as an asymptomatic, gradually enlarging scaly or crusted erythematous plaque, which is sharply demarcated and superficial in palpation. While sunlight and chronic arsenic intake or exposures are well-known risk factors, it is debatable whether the human papillomavirus (HPV) has a significant role.⁶

Pigmented BD is a rare form of the disease, which represents less than 2% of all lesions. In one study, only seven cases out of 420 cases of BD were found to be pigmented.⁷ The occurrence of

the lesion on the finger is even rarer. To the best of our knowledge, so far only one case with pigmented BD of the finger has been reported.⁷ Herein, we reported on an unusual case of pigmented BD occurring on the finger of a 20-year-old white, skin type III, Iranian woman.

Case Report

A 20-year-old white, Fitzpatrick skin type III, Iranian woman was referred to our clinic with a four-year history of a gradually enlarging lesion of the pulp of her right fourth finger. The patient had not been complaining of any symptoms and had not considered seeking medical attention before visiting us. There was no history of exposure to arsenic, tar, or radiation. There was no personal or familial history of any skin or internal malignancy.

On physical examination, she was noted to have a solitary hyperpigmented patch on the right fourth finger, measuring 1 cm in its greatest diameter. The lesion, which appeared irregularly shaped, had a well-defined margin and was homogeneously brown and had a smooth surface (Figure 1). There was no nodularity or induration in the lesion or in its surrounding skin.

Authors' affiliations: *Center for Research and Training in Skin Diseases and Leprosy, Tehran University of Medical Sciences, **Department of Dermatology, Army Medical University, Tehran, Iran.

Corresponding author and reprints: Alireza Firooz MD, Center for Research and Training in Skin Diseases and Leprosy, Tehran University of Medical Sciences, Tehran, Iran.
Tel: +98-218-897-8190, Fax: +98-218-897-8190,
E-mail: firozali@sina.tums.ac.ir.

Accepted for publication: 12 July 2006

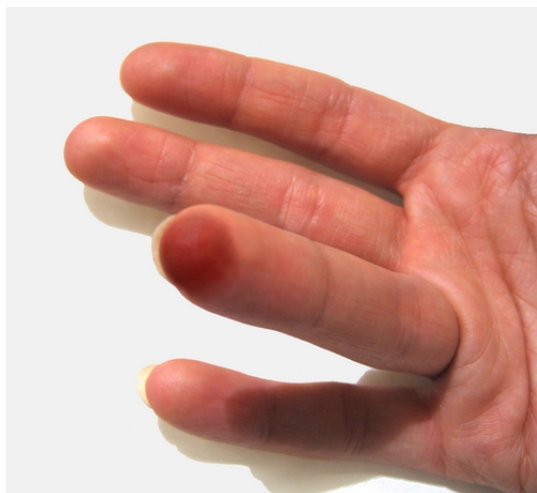

Figure 1. Pigmented Bowen's disease: Hyperpigmented patch on the pulp of the right fourth finger.

A skin biopsy was taken with the clinical suspicion of malignant melanoma. The specimen was then fixed, paraffin-embedded, and then stained with hematoxylin and eosin. Microscopic examination of the specimen revealed diffuse full-thickness keratinocytic atypia with loss of polarity, atypical mitotic figures, and many dyskeratotic cells as well as vacuolization of the keratinocytes of the upper epidermis (Figures 2 and 3). There was regular acanthosis with diffuse hyperkeratosis and thickening of elongated rete ridges. The papillary and subpapillary dermis were fibrotic and the vessels showed wall thickening. The histological pattern was compatible with the diagnosis of pigmented BD. Surgical treatment

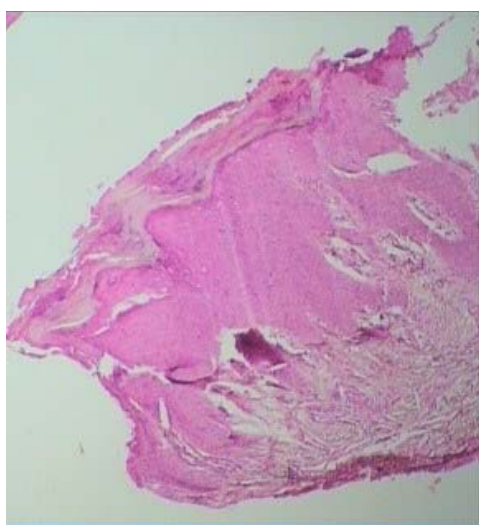


Figure 2. Pigmented Bowen's disease: Regular acanthosis with diffuse parakeratosis and elongation of rete ridges (Hematoxylin and eosin, x40).

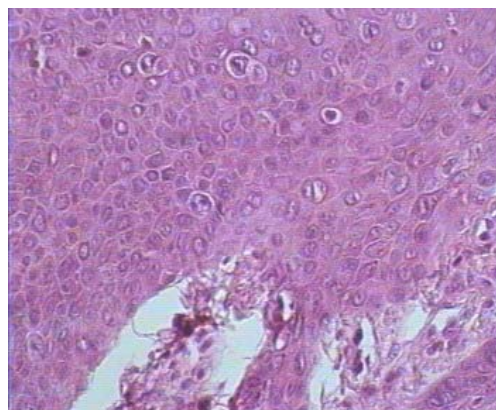


Figure 3. Pigmented Bowen's disease: Keratinocyte atypia with loss of polarity, atypical mitotic figures, and many dyskeratotic cells as well as vacuolization of the keratinocytes of the upper epidermis and melanin pigment increase in the lower epidermis (Hematoxylin and eosin, x100).

was then considered and the patient underwent complete excision of the lesion. Follow-up of the patient, six months later, showed no recurrence.

Discussion

BD is a squamous cell carcinoma *in situ*, which commonly occurs on sun-exposed areas of the head, neck, and especially in women, on the lower extremities.¹⁻⁵ It is more common among elderly people with a very low incidence under the age of 30 years.^{3, 8} The clinical presentation of BD is a gradually growing, erythematous, well-demarcated plaque with a scaly or crusty surface that may be eroded or ulcerated.⁹

Pigmented BD is an unusual form of the disease, which rarely has been reported. In one study, a review of 420 BD lesions revealed that only 7 (1.7%) were pigmented.⁷ Pigmented BD usually presents as a nonuniformly pigmented plaque with a scaly or verrucous surface that should be differentiated from seborrheic keratosis, pigmented actinic keratosis, solar lentigo, basal cell carcinoma, blue nevus, melanocytic nevi, and melanoma.^{5, 7, 10} However, our patient presented with a uniformly pigmented, flat patch on her finger. To the best of our knowledge, only one reported case of pigmented BD involving the finger has so far been reported which, in contrary to our patient, occurred in an old patient.⁷

Several factors such as sun exposure, arsenic, viruses, trauma, and radiation have been described as possible etiological factors of BD, including its pigmented variant.^{5, 6} Since BD involved sun-

exposed anatomical sites in our patient, sunlight could play an important role in this patient. However, there was no evidence in favor of possible chronic arsenic intoxication, trauma, and exposure to radiation.

Another potential etiological factor in the development of BD is the HPV; although, its role in the development of nongenital BD has been less well-defined.¹¹ It seems that HPV is mainly related to the development of BD in nonsun-exposed areas such as ano-genital area, palms, soles, and mucous membranes, but reviewing the literature, some cases of nongenital BD positive for HPV types 2, 16, 18, 34, and 35 have been also reported.^{12, 13} Kettler et al suggested that clinical factors that can be associated in the presence of HPV in nongenital BD include black race, palmoplantar involvement, verrucous clinical appearance, and young age.⁶ Among them, only the last one was the case in our patient.

Recently, dermoscopy has been considered as a helpful tool for increasing the diagnostic accuracy of BD; although, its sensitivity and specificity are not fully determined. Dermoscopic investigation of 21 histopathologically-proven BD showed that glomerular vessels plus a scaly surface were the most frequent combination of criteria in pigmented and nonpigmented BD.⁹ In pigmented BD, small brown globules and/or homogeneous pigmentation was seen as well. On the other hand, in another study, dermoscopic examination gave no contribution concerning the correct classification of a pigmented BD lesion.¹⁴

Our case is noteworthy for its unusual clinical presentation and location as well as for its occurrence in a young individual. Pigmented expression of BD is a rare and unusual form of the disease, but should be considered in the differential diagnosis of pigmented lesions, particularly malignant melanoma.

References

- 1 Callen JP, Headington J. Bowen's and non-Bowen's squamous intraepidermal neoplasia of the skin. Relationship to internal malignancy. *Arch Dermatol.* 1980; **116**: 422 – 426.
- 2 Eedy DJ, Cavin AT. Thirteen year retrospective study of Bowen's disease in northern Ireland. *Br J Dermatol.* 1987; **117**: 715 – 720.
- 3 Kossard S, Rosen R. Cutaneous Bowen's disease. An analysis of 1001 cases according to age, sex, and site. *J Am Acad Dermatol.* 1992; **27**: 406 – 410.
- 4 Cox NH. Body site distribution of Bowen's disease. *Br J Dermatol.* 1994; **130**: 714 – 716.
- 5 Papageorgiou PP, Koumariou AA, Chu AC. Pigmented Bowen's disease. *Br J Dermatol.* 1998; **138**: 515 – 518.
- 6 Kettler AH, Rutledge M, Tschen JA, Buffone G. Detection of human papillomavirus in nongenital Bowen's disease by *in situ* DNA hybridization. *Arch Dermatol.* 1990; **126**: 777 – 781.
- 7 Ragi G, Turner MS, Klein LE, Stoll HL Jr. Pigmented Bowen's disease and review of 420 Bowen's disease lesions. *J Dermatol Surg Oncol.* 1988; **14**: 765 – 769.
- 8 Thestrup-Pedersen K, Ravnborg L, Reymann F. Morbus-Bowen. A description of the disease in 617 patients. *Acta Derm Venereol.* 1988; **69**: 236 – 239.
- 9 Kolm I, Di Stefani A, Hofmann-Wellenhof R, Fink-Puches R, Wolf IH, Richtig E, et al. Dermoscopy of Bowen's disease. *Br J Dermatol.* 2004; **150**: 1112 – 1116.
- 10 Krishnan R, Lewis A, Orengo IF, Rosen T. Pigmented Bowen's disease (squamous cell carcinoma *in situ*): a mimic of malignant melanoma. *Dermatol Surg.* 2001; **27**: 673 – 674.
- 11 McGrae JD, Greer CCE, Manos MM. Multiple Bowen's disease of the fingers associated with human papillomavirus type-16. *Int J Dermatol.* 1993; **32**: 104 – 107.
- 12 Ikenberg H, Gissman L, Gross G, Grussendorf-Conen EI, zur Hausen H. Human papillomavirus type-16-related DNA in genital Bowen's disease and Bowenoid papulosis. *Int J Cancer.* 1983; **32**: 563 – 565.
- 13 Cobb MW. Human papillomavirus infection. *J Am Acad Dermatol.* 1990; **22**: 547 – 566.
- 14 Stante M, De Giorgio V, Massi D, Chiarugi A, Carli P. Pigmented Bowen's disease mimicking cutaneous melanoma: clinical and dermoscopic aspects. *Dermatol Surg.* 2004; **30**: 541 – 544.