

---

## Case Report

---

# Papillary Serous Carcinoma Arising from Adenomyosis Presenting as Intramural Leiomyoma

Narges Izadi-Mood MD\*, Nasrin Samadi MD\*, Soheila Sarmadi MD\*,  
Zahra Eftekhari MD\*\*

---

**Adenocarcinoma arising from adenomyosis uteri is rare. Herein, we reported a patient with papillary serous carcinoma arising from adenomyosis. The patient was a 61-year-old woman who received tamoxifen for treatment of her breast cancer over the past five years. In hysterectomy specimen taken for investigating her uncontrolled bleeding with suspicion of uterine myoma, multiple adenomyotic foci were found in the uterine wall. In one of these foci, papillary serous carcinoma was found. No evidence of tumor was seen in endometrial surface, peritoneum, and both adnexa.**

*Archives of Iranian Medicine, Volume 10, Number 2, 2007: 258 – 260.*

---

**Keywords:** Adenomyosis • endometrial carcinoma • papillary serous carcinoma • tamoxifen

### Introduction

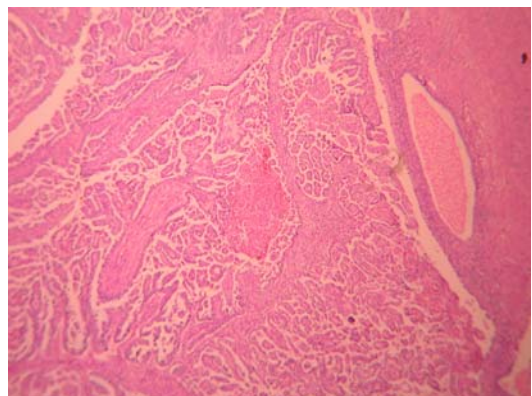
Endometrial adenocarcinoma is often accompanied by adenomyosis, but it is very rare to see adenocarcinoma arising from adenomyotic foci.<sup>1</sup> There have been only about 32 documented reports of malignant transformation of adenomyosis in our literature review.<sup>1-4</sup> Thus the clinicopathological features and outcome of the patients are not well understood. The most common endometrial carcinoma in tamoxifen-treated patients is serous carcinoma.<sup>5</sup>

We report a case of papillary serous carcinoma arising from adenomyosis in a woman with the history of five-years of tamoxifen therapy for breast cancer.

### Case Report

A 61-year-old postmenopausal woman, who

had a history of breast cancer (invasive lobular carcinoma), underwent mastectomy and received tamoxifen for the past five years. She underwent hysterectomy and bilateral salpingo-oophorectomy, due to uncontrolled postmenopausal bleeding for three months with suspicion, of uterine myoma, in another center on July 2003. No endometrial curettage and Pap smear were performed before hysterectomy. On macroscopic examination, multiple hemorrhagic cysts and a well-defined tumor in the myometrium measuring one centimeter in its maximal diameter were identified. Endometrium showed no gross abnormality. Microscopic examination revealed papillary serous



**Figure 1.** Papillary serous carcinoma arising from adenomyotic focus (low power).

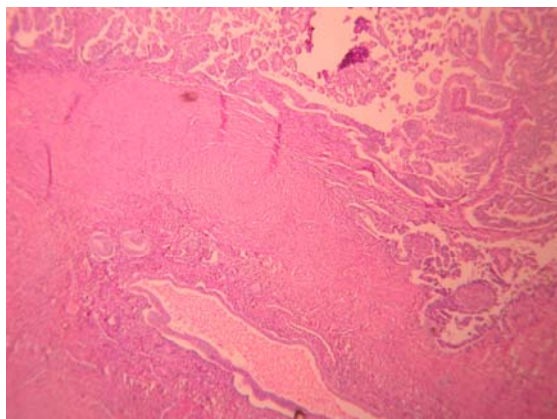
---

**Authors' affiliations:** \*Department of Pathology, \*\*Division of Oncology, Department of Gynecology, Mirza Koochak Khan Hospital, Tehran University of Medical Sciences, Tehran, Iran.

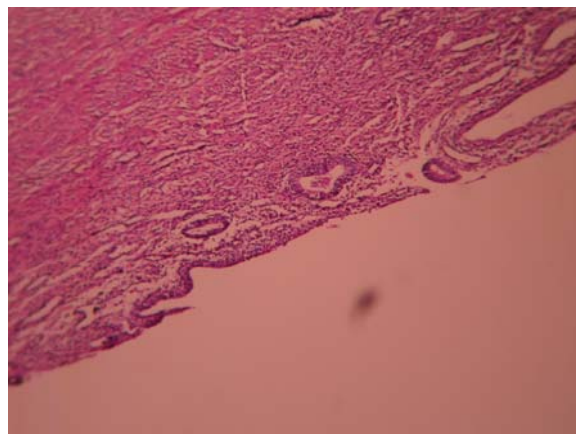
**Corresponding author and reprints:** Narges Izadi-Mood MD, Department of Pathology, Tehran University of Medical Sciences, Tehran, Iran. Tel: +98-218-890-6767,

Fax: +98-218-890-4172, E-mail: nizadimood@yahoo.com.

Accepted for publication: 26 June 2006



**Figure 2.** Papillary serous carcinoma adjacent to a normal adenomyotic focus (low power).



**Figure 4.** Atrophic endometrium (low power).

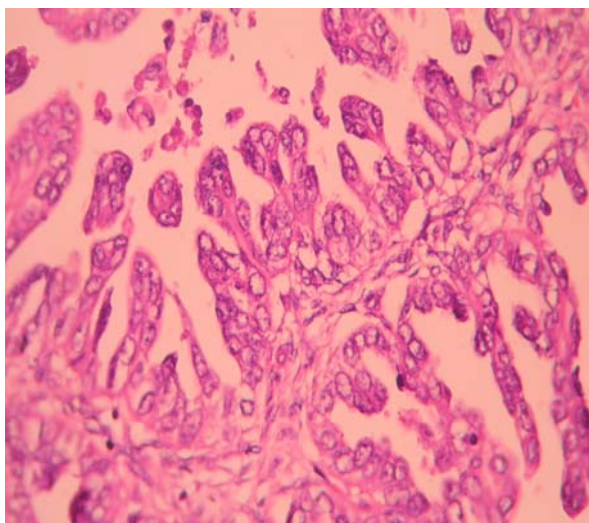
carcinoma within an adenomyotic focus of the myometrium (Figures 1, 2, and 3). In other regions, multiple foci of adenomyosis with dysplastic changes were found. Endometrium was totally examined, showing only cystic atrophy with no tumor involvement (Figure 4). No cervical, parametrial tissue, and adnexal involvements were seen. The patient received pelvic and intracavitary radiation. By January 2006, the patient did not show any evidence of recurrence or metastasis after two and a half years of follow-up.

### Discussion

Sampson or Colman's criteria for the diagnosis of carcinoma arising from adenomyosis include: a) the carcinoma must not be situated in the endometrium or elsewhere in the pelvis; b) the carcinoma must be seen to arise from the epithelium of adenomyosis and not to have invaded

from another source; and c) endometrial (adenomyotic) stromal cells must be present to support a diagnosis of adenomyosis.<sup>2</sup> Koshiyama et al also emphasized the necessity of demonstrating the presence of either transition or continuity between benign glands and the carcinomatous glands to prove that the latter has been arisen from the former.<sup>2</sup> Our case satisfied all of the described criteria.

In our literature review, we found only 32 well-documented cases of malignant tumors arising from adenomyosis. Koshiyama et al reported four patients with adenocarcinoma in adenomyosis and reviewed 26 previously-reported cases.<sup>2</sup> We could not find any information on the histological subtypes of the nine reported cases during 1897 – 1979, but in the evaluated cases after that time until 2002 (11 cases), only one documented case of papillary serous carcinoma was reported. Ichikawa et al reported a case of endometrioid adenocarcinoma in adenomyosis coexisting with pregnancy.<sup>4</sup> Takeuchi et al reported a case of invasive endometrioid adenocarcinoma arising from uterine adenomyosis involving the rectosigmoid colon.<sup>3</sup> Buckley and Ismail showed that 67% of patients treated with tamoxifen have poorly differentiated or poor prognosis variants of endometrial carcinoma (e.g., serous carcinoma, clear cell carcinoma, or malignant mixed Mullerian tumor).<sup>5</sup> Our patient was found to have papillary serous carcinoma too, which made this case unique in the sense that we could not find any similar cases that arose from adenomyosis. In conclusion, the rare occurrence of adenocarcinoma of the uterus within adenomyosis must be differentiated from the more common event of extension of the tumor from the surface to adenomyotic foci. In our



**Figure 3.** High-grade nuclear abnormality lining the papillary frond (high power).

patient, the total endometrium was studied to exclude the possibility of the previously-mentioned phenomena; no tumor involvements were found in other sites. The delay in the diagnosis of this type of tumor may be due to the finding of no tumor in endometrial curettage. Therefore, many patients may be diagnosed with advanced stages of the disease. Fortunately, our patient was diagnosed in early stage and treated successfully. Therefore, every patient who receives tamoxifen should be followed by pelvic ultrasonography for early diagnosis of any myometrial lesions.

### References

- 1 Sasaki T, Sugiyama T, Nanjo H, Hoshi N, Murakami M, Sugita A, et al. Endometrial adenocarcinoma arising from adenomyosis: report and immunohistochemical analysis of an unusual case. *Pathol Int.* 2001; **51**: 308 – 313.
- 2 Koshiyama M, Suzuki A, Ozawa M, Fujita K, Sakakibara A, Kawamura M, et al. Adenocarcinomas arising from uterine adenomyosis: a report of four cases. *Int J Gynecol Pathol.* 2002; **21**: 239 – 245.
- 3 Takeuchi K, Yamanaka Y, Hamana S, Ohara N, Maruo T. Invasive adenocarcinoma arising from uterine adenomyosis involving the rectosigmoid colon. *Int J Gynecol Cancer.* 2004; **14**: 1004 – 1006.
- 4 Ichikawa Y, Takano K, Higa S, Tanabe M, Wada A, Sugita M, et al. Endometrial carcinoma coexisting with pregnancy, presumed to drive from adenomyosis: a case report. *Int J Gynecol Cancer.* 2001; **11**: 488 – 490.
- 5 Buckley CH, Ismail SM. Pathology of conception and hormonal therapy. In: Fox H, Wells M, eds. *Hains and Taylor Obstetrical and Gynecological Pathology.* 5th ed. London: Elsevier; 2003: 1076 – 1080.