
Photoclinic

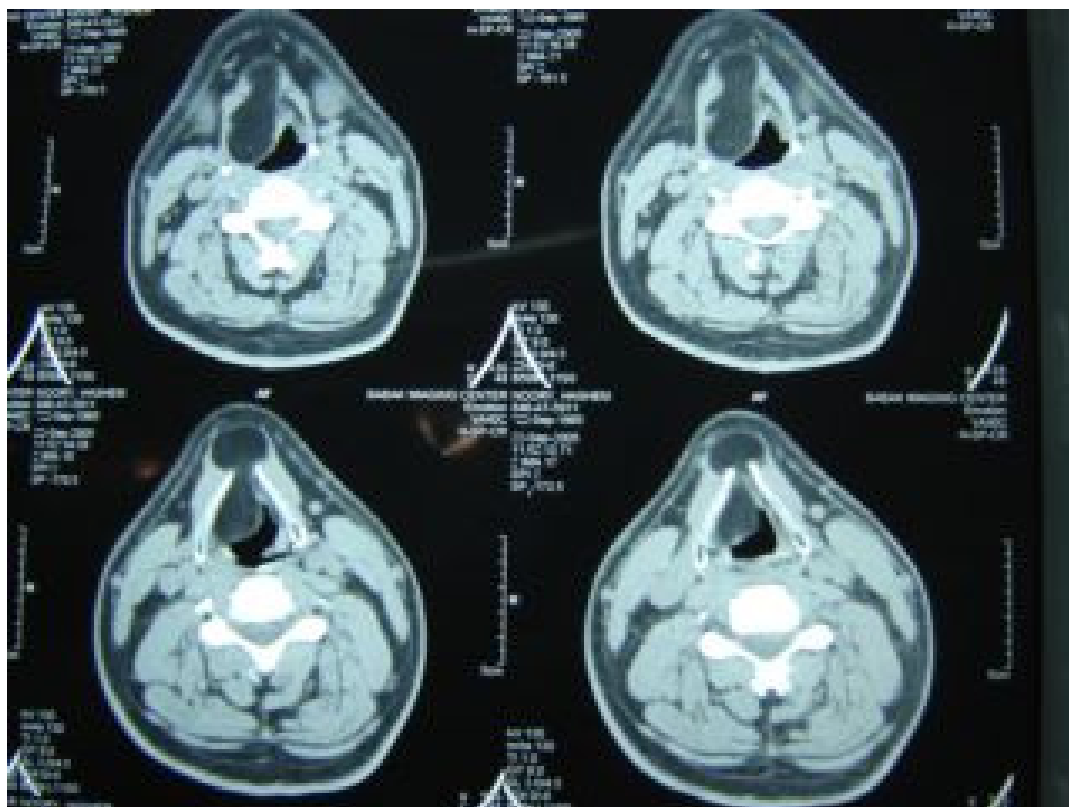


Figure 1. CT of the neck illustrating a well-circumscribed lesion with a low density.

A 40-year-old man presented with voice change that had progressed gradually over six months. He also had progressive dysphasia and mild dysphonia without airway obstruction or stridor. Indirect laryngoscopy with mirror showed an exten-

sive submucosal swelling that obstructed the right side of the supraglottic larynx. Moreover, the right vocal cord movements were decreased due to a mass effect.

Computed tomography (CT) of the neck revealed a well-circumscribed low density lesion (Figure 1).

Masoud Naderpour MD*, Nikzad Shahidi MD*, Amir Daryani MD*, Kamelia Chavoshi Nejad BA*

Authors' affiliation: *Department of Otolaryngology Head and Neck Surgery, Tabriz University of Medical Sciences, Tabriz, Iran.

•Corresponding author and reprints: Amir Daryani MD, Department of General Surgery, Imam Reza Hospital, Tabriz University of Medical Sciences, Tabriz, Iran.

Tel: +98-914-313-0008

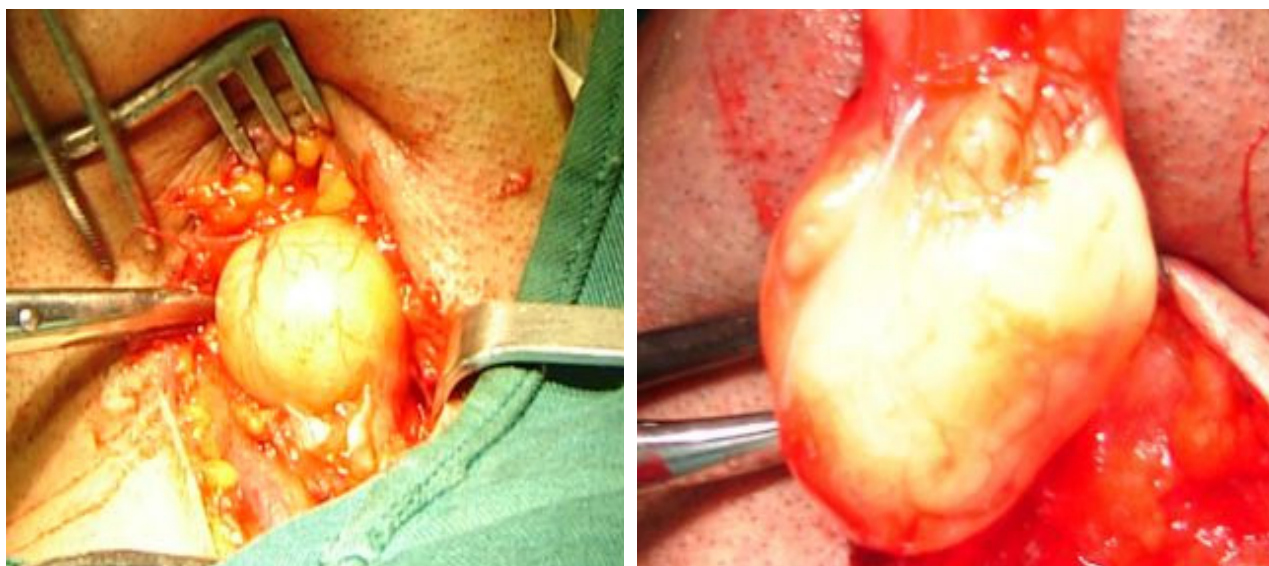
Fax: +98-411-288-9110

E-mail: daryanimd@gmail.com

Accepted for publication: 18 June 2008

What is Your Diagnosis?

See pages 678 – 679 for the diagnosis.



Figures 2 and 3. The encapsulated mass was removed intact by surgery.

The patient underwent surgery and an encapsulated mass was removed intact (Figures 2 and 3). The patient was discharged uneventfully, after 48 hours. Furthermore, he did not have hoarseness, dysphasia, or any other complications after six months of follow-up; his larynx had a normal appearance during examinations. Also, pathologic results reported mature adipocytes with uniform appearance with fibrous bands in some sections that were represented an encapsulated tumor attached to the larynx. So, the pathologic examination detected the lipoma as it was expected.

Lipomas are the most prevalent benign tumors with mesenchymal origin. Less than 15% of all lipomas are in the head and the posterior part of the neck. Anterior part of the neck, infratemporal fossa, oral cavity, parotid gland, pharynx, and larynx are other possible but less common places for lipomas.

The clinical symptoms include dysphasia, dyspnea, and hoarseness. Endoscopies show a plane or pediculate mass and pathologic sections detect a tumor with mature adipose that are usually capsular. Laryngeal lipoma has a variable range of treatments from endoscopic excision to open surgery.

Lipomas are common but laryngeal lipomas are quiet rare. Less than 1% of laryngeal benign

tumors are lipomas. It occurs in the sixth or seventh decades of life with a male to female ratio of 5:14. Up to now, less than 100 cases have been reported of which 78 cases were listed by Zakrzewski in 1965. Laryngeal lipoma could be intrinsic or extrinsic. Intrinsic lipomas are not common and they occur in regions such as false vocal cords, aryepiglottic folds, and epiglottis in which fat forms some portion of the subepithelial structure. The glottic is the rarest one.¹

Macroscopically, lipomas have different sizes. They are usually flat or lobular, well demarcated, and capsular with a yellowish color. Their endoscopic appearance is completely variable from submucosal mass to pediculate intraluminal mass.²

Microscopically, lipomas are composed of mature adipocytes which vary in shape and size. Also, they have a large central vacuole which displaces the nucleus to the periphery of the cell. Usually, lipomas are vascular but sometimes distended lipocytes compress the vascular network.

Differential diagnoses of laryngeal lipomas include leiomyoma, chondroma, papilloma, and neurofibroma. However, lipoma could be easily distinguished from these lesions by its low density in CT and its signal characteristics in magnetic resonance imaging (MRI) which has a high signal

in T₁- and a low signal in T₂-weighted images.³

Nonpediculate large tumors need to be removed completely through an external approach such as thyrotomy, transhyoid, or lateral pharyngotomy to have an appropriate exposure to eliminate recurrence.⁴ Furthermore, it is necessary to preserve the superior and recurrent laryngeal nerves in order to prevent damage to laryngeal functions.

Surgery is necessary in case of cosmetic or presence of pressure symptoms.⁵ We suggest an external approach for large lipomas (>2 cm), because en-block endoscopy would be difficult. Moreover, some large lipomas could be a low-grade liposarcoma that would be better removed

completely with its capsule.¹

References

- 1 Bastian RW. Benign mucosal disorders and neoplasms. In: Cummings CW, eds. *Otolaryngol Head and Neck Surg*. Vol 3. St. Louis: Mosby; 1986: 1965 – 1987.
- 2 Wenig BM. Lipomas of the larynx and hypopharynx: a review of the literature with the addition of three cases. *J Laryngol Otol*. 1995; **109**: 353 – 357.
- 3 Yoskovitch A, Cambronero E, Said S, Whiteman M, Goodwin WJ. Giant lipoma of the larynx: a case report and literature review. *Ear Nose Throat J*. 1999; **78**: 122 – 128.
- 4 Trizna Z, Forrai G, Toth B, Banhidly FG. Laryngeal lipoma. *Ear Nose Throat J*. 1991; **70**: 387 – 388.
- 5 Cummings CW. *Otolaryngology Head and Neck Surgery*. 4th ed. St. Louis: Mosby; 2005: 2563.