

---

 Review Article
 

---

## Snoring and Obstructive Sleep Apnea

Mansoor Madani DMD MD\*

---

The number of patients who suffer from snoring and sleep apnea in Iran has been increasing in proportionate to the rest of the world as the prevalence of obesity has soared within the last two decades. This pandemic obesity is blamed on consumption of more energy-dense, nutrient-poor foods with high levels of sugar and saturated fats. Obesity is one of the major contributing factors of obstructive sleep apnea. The number of people snoring in Iran is not well established, but since many years ago this bizarre behaviour was looked upon as an annoying sound that some people have and it was thought that they have to live with it. It was not until early twentieth century that scientists began to relate an association between snoring, obesity, and sleep-related disorders. At present time, it is well documented and universally agreed that snoring as well as sleep apnea are far more prevalent in societies and can lead to other serious illnesses including heart attack, stroke, and even nocturnal death. Obstructive sleep apnea is a term used to describe cessation of breathing while sleep for a period of 10 seconds or more and repeated over five times per hour of sleep. In this article, we review various methods of surgical treatments and the long-term relapse potential for each.

*Archives of Iranian Medicine, Volume 10, Number 2, 2007: 215 – 226.*

---

**Keywords:** Obstructive sleep apnea • snoring • surgical alternatives • upper airway obstruction

### Introduction

Once the obstructive sleep apnea, its symptoms, and clinical findings were described, surgeons began to experiment with various methods of treatments. After many years of modifying all sorts of treatments they came up to a very important conclusion that “may be the surgical cure for sleep apnea is not as simple as any other medical disorder.” The reason lies in the understanding of various factors that contribute to formation of apnea. Some of those are due to patient’s anatomical structures, which are slightly easier to rectify. The others may relate to patient’s chronological age, gender, habits, or associated illnesses including obesity. We cannot address all factors that contribute to snoring and obstructive

sleep apnea, but in this paper we will first describe the prevalence, anatomical considerations, and biological as well as clinical principles. We will then discuss various surgical procedures and finally, explain the advantages as well as disadvantages of each procedure.

### Prevalence

According to the latest statistics of World Health Organization (WHO), globally, there were more than 1.6 billion overweight adults and at least 400 million obese in 2005 on earth. WHO further projects that by 2015, approximately 2.3 billion adults will be overweight and more than 700 million will be obese. Amazingly, over 20 million children under age of five years were overweight in 2005.<sup>1</sup> Obese and overweight individuals have much higher chance of snoring or having obstructive sleep apnea. They are additionally, more prone to develop chronic diseases, including type II diabetes, cardiovascular disease, hypertension, stroke, and certain forms of cancer.<sup>2</sup> Often coexisting in developing countries with under-nutrition, obesity is a complex condition with serious social and psychological dimensions,

---

**Author’s affiliation:** \*Department of Oral and Maxillofacial Surgery, Capital Health System, Trenton, USA, Department of Oral and Maxillofacial Surgery, Temple University Hospital, Philadelphia, USA

**•Corresponding author and reprints:** Mansoor Madani DMD, MD, Center For Corrective Surgery, 15 North Presidential Blvd., Suite 301, Bala Cynwyd PA 19004, USA.

E-mail: fmadani@pobox.upenn.edu.

Accepted for publication:24 January 2007

affecting virtually all ages and socioeconomic groups. The obesity rates unfortunately has risen three-fold or more since 1980 in some areas of North America, the United Kingdom, eastern Europe, the Middle East (including Iran), the Pacific Islands, Australia, Asia, and China. The obesity epidemic is not restricted to industrialized societies; this increase is often faster in developing countries than in the developed world. Of the total estimated population of Iran, which is reported to be almost 70,000,000, it is estimated that 40% of the adult population of Tehran, Iran are overweight and 23.1% are obese<sup>3-4</sup> (Tables 1 and 2).

### Clinical manifestations

One of the reasons why sleep apnea is under-diagnosed is that it happens when individuals sleep. Most adults who snore and have sleep apnea continue to deny that they suffer from any problems simply because they cannot hear themselves snoring or are not aware of their symptoms. Clinical manifestations of obstructive sleep apnea could be divided into nocturnal and daytime symptoms. Of course, at the top of nocturnal symptoms is very loud snoring. The other nighttime symptoms are fragmented sleep, restless sleep, stop breathing while sleep, gasping for air or choking, esophageal reflux, dry mouth, nocturia, palpitation, and nightmare to list only a few. Daytime symptoms are morning headaches, daytime sleepiness, fatigue, depression and mood alterations, sexual dysfunction as a result of hypoxemia, hearing loss, cognitive deficiencies, automatic behavior, reduced mental alertness and short-term memory loss, hypnogenic hallucinations, and even family quarrels. Systemic consequences of apnea may include hypertension, cardiac arrhythmias, systemic and pulmonary hypertension, cor-pulmonale, chronic carbon dioxide retention and polycythemia, left ventricular dysfunction, myocardial infarction, and

**Table 1.** Age-standardized estimates for BMI  $\geq$  25 kg/m<sup>2</sup> by country for ages 15 – 100 years, estimates for 2005.

Country	Sex	Prevalence (%)
Iran (Islamic Republic of)	Females	57.8
Iran (Islamic Republic of)	Males	48.5

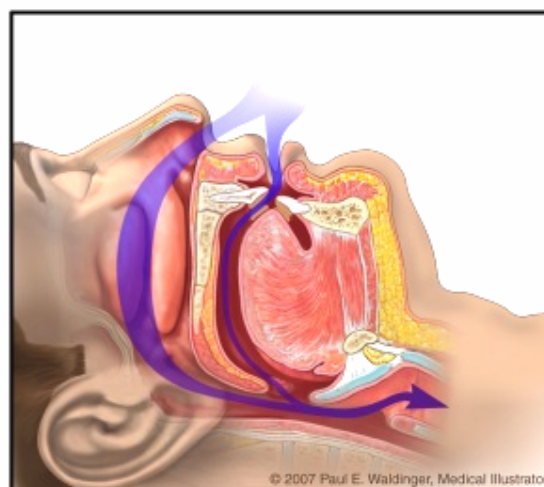
**Table 2.** Age-standardized estimates for BMI  $\geq$  30 kg/m<sup>2</sup> by country for ages 15 – 100 years, estimates for 2005.

Country	Sex	Prevalence (%)
Iran (Islamic Republic of)	Females	27.0
Iran (Islamic Republic of)	Males	10.0

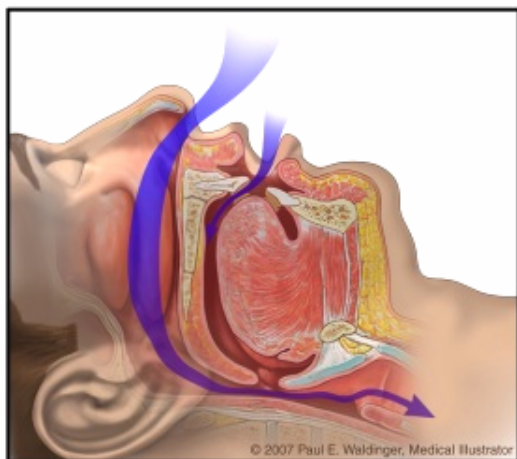
stroke, leading to death.<sup>5-9</sup> Finally, the impact of snoring and sleep apnea may result in sleeping of bed partners in separate rooms or even divorce.

### Predisposing factors

One of the most important predisposing factors is obesity. Over two-thirds of the patients with obstructive sleep apnea are  $>20\%$  above their ideal body weight. Generally, obesity is also associated with larger neck size. If an individual's neck circumference is greater than 42.5 cm, with double chin, the chance of apnea increases significantly.<sup>10</sup> This in part is related to the anatomical changes that happen with increased body mass. First, the tongue is pushed up, hence reducing the size of the oral airway. More importantly, if patient sleeps on his/her back the airway is obstructed from the base of tongue pressing against it.<sup>11-14</sup> Also radiographic and magnetic resonance imaging (MRI) studies of overweight and obese patients show a reduction in size of the hypopharyngeal airway. But airway blockage could be at many levels including the obstructive tonsils and adenoids, nasal obstruction from a deviated septum or enlarged nasal turbinate, and other upper airway structures constricting the airway. Craniofacial as well as maxillofacial anomalies can play an important role in obstructive sleep apnea cases. In particular, patients with bimaxillary or mandibular retrognathism with a receded chin are more prone to develop signs of obstructive sleep apnea (Figures 1 – 3). This brings an important issue to our profession's attention when treating patients



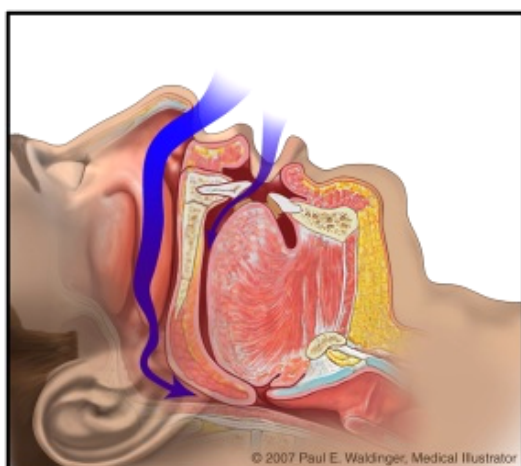
**Figure 1.** Normal airway: no obstruction in the upper airway is noted.



**Figure 2.** Hypopnea; partial obstruction of the upper airway. There is a partial narrowing of the pharyngeal airway. The vibration of tissues in the airway to include uvula, soft palate, obstructive tonsils, deviated septum, hypertrophied nasal turbinate and mandibular or bimaxillary retrognathism are amongst various factors causing snoring and obstructed sleep apnea.

with severe mandibular prognathism to avoid impinging the airway by merely moving the mandible backward, hence obstructing the airway.

Other factors that could predispose an individual to apnea are use of central nervous system (CNS) depressants: alcohol and sleeping pills that can cause a more relaxed airway, resulting in its collapse. Pulmonary diseases such



**Figure 3.** Obstructive sleep apnea; the flow of air is blocked through the upper airways and patient is deprived of receiving vital oxygen deemed necessary for normal body function.

as chronic obstructive pulmonary diseases (COPD) and restrictive or neuromuscular diseases of the lungs can cause airway problems as well.

### Diagnostic tools

One of the most basic methods in diagnosing a patient with sleep apnea is simply asking them and their bed partners to complete a comprehensive questionnaire if they do snore or stop breathing at night. In our experience, most bed partners already have the answer. It is highly recommended that all medical and dental practitioners include questions in their patient's medical health questionnaires regarding snoring and patient's sleep problems. In fact dental practitioners could be the first health-care professionals to detect airway obstruction by careful evaluation of the patient's intra- and extra-oral structures. That should include assessing all structures discussed in the previous section.

One of the simplest methods in a dental office to evaluate the airway is a cephalometric radiography, plain lateral neck radiography of the airways.<sup>15 - 16</sup> Although this radiograph is most useful for assessing maxillofacial skeletal abnormalities, the true value of this study for assessing the obstructive sleep apnea is debated. Unlike an MRI or a three-dimensional computed tomography (CT), a cephalometric radiography shows a two-dimensional view of the airway. On the other hand, CT and MRI studies are rarely performed in the work-up of obstructive sleep apnea because they do provide little information to guide therapeutic intervention; they are expensive, and they expose patients to unnecessary radiation. It is recommended that all patients with moderate to severe apnea should have an evaluation of their thyroid function.

Polysomnography (sleep apnea studies) is the gold standard test for diagnosing sleep apnea. Diagnostic information gathered in a sleep laboratory includes the stages of sleep and the number and types of apneic events. Also performed are continuous blood oxygen saturation monitoring and continuous electrocardiography (ECG) tracing.

### Medical managements

Since 1981, continuous positive airway pressure (CPAP) has been the most commonly prescribed nonsurgical method of treatment for obstructive sleep apnea. It acts as a forceful pneumatic stent to prevent airway collapse. There

are various types of CPAP now available that administer air through a nasal mask, nasal prongs, or a facial mask, covering the nose and mouth together. The pressure used ranges from 4 – 20 cm H<sub>2</sub>O with an average starting point of 8 – 10 cm H<sub>2</sub>O. Higher levels (>15 cm H<sub>2</sub>O) often are not well tolerated. The CPAP does not cure or alter the underlying obstructive sleep apnea but rather provides daily relief from the snoring, apneas, hypoxias, and consequent daytime symptoms.

The main problem with CPAP is the fact that the treatment requires the patient to be compliant in wearing a mask at night, which some consider uncomfortable. In our follow-up questionnaires of over 7,000 patients, around 60% of patients did not tolerate or continue to use it beyond two years. The other reasons for discontinuing to use CPAP were physical discomfort associated with wearing the unit, nasal and oral dryness, dislodgement of the mask during sleep, noise, and for social reasons.

Oral appliances or mandible advancement devices alter the position of the tongue base and mandible, respectively, by advancing their position in an effort to relieve the obstruction, reducing snoring as well as treating the sleep apnea. Once again compliance is an important issue and we have seen cases with appliance-induced temporomandibular joint derangement (TMD) and periodontal problems, teeth movements, and posterior open bite as well as decreased anterior overjet.

### **Surgical managements**

Surgical intervention, when properly chosen, can in fact significantly benefit certain patients. We must, however, stress that patient's expectation and the surgeon's expertise can play an important role. There is no single, safe surgical procedure available today to completely eliminate the obstructive sleep apnea. One may say that tracheostomy could be an option but not a realistic option for all patients. Same is true regarding orthognathic surgery, which is not indicated in all cases; it has many potential complications and it is costly<sup>17-18</sup>.

On the other hand, surgical treatment of snoring alone is much easier although there are no guarantees that they work for all or last forever.

### **Presurgical considerations**

We obtain a panoramic and lateral cephalometric radiograph from all patients to

visually asses the soft tissue structures in the airway as well as evaluating the maxillofacial skeleton, hyoid bone and tongue position, maxillary sinus as well as nasal septal deviations and obstructions, and many other structures seen in these types of X-rays. Utilizing a zero angle intra-oral camera, our findings are shared and explained to them in a monitor in front of patients. The same camera is used to visualize the nasal obstructions for various problems including presence of polyps, septal deviations, and obstructive nasal turbinates. There are numerous surgical procedures available to treat snoring and sleep apnea.<sup>19-35</sup> In this article we review few of the most commonly methods.

### **Nasal radioablation**

Nasal turbinate dysfunction is universal. We all have turbinate dysfunction at some instances in our lives. But some suffer from chronic nasal obstruction due to turbinate hypertrophy or dysfunction. The symptoms range from total nasal obstruction to mild congestion, nasal snoring, heavy breathing from the nose, postnasal drip and rhinorrhea, headaches, facial pain, and in some cases sleep disorders. A chronic stuffy nose can impair normal breathing, force patients to breathe through the mouth, and often affects their daily activities.

Since 1997, we have performed hundreds of nasal turbinate radioablation with great success. This is a simple, outpatient procedure preformed in an extremely brief period of time.<sup>36</sup> First, a cotton role soaked with a solution of equal amounts of 4% Xylocaine and a nasal decongestant is placed in the nasal cavity for a period of one minute. Then about 2 mL of 2% Xylocaine with 1:100,000 epinephrine is injected in the inferior turbinate with a 27G needle. A Coblation reflex wand 45 (or similar devices such as Somnus nasal probe or Elman nasal tip) is used to deliver heat to the site. The Coblation probe is the safest and easiest to use with a setting of 6, which is placed in the inferior turbinate only and kept for a period of 10 seconds in each spot. For excessively large turbinates two lesions may be requires. Repeated ablation may lead to scab formation, bleeding, and dryness. If Elman surgical unit is used, due to its rapid raise of the temperature caution should be taken to avoid overheating of the tissue leading to inferior turbinate bone necrosis. On the other hand, Somnus nasal probe has a control panel that keeps the tissue temperature at almost 85°C. However,

this unit is the slowest of all other systems available in the market.

We have added another modification to our turbinate radioablation and that takes place at the conclusion of the procedure where the nasal turbinates are out-fractured as well utilizing a nasal speculum and a flat surfaced instrument. This technique will allow both mechanical bony expansions as well as radiofrequency assisted thermal ablation. The nasal cavity is then packed with a small cotton role soaked with a nasal decongestant. Patient removes the packing the following day.

Postoperatively, patients are advised to avoid blowing vigorously from their nose for four weeks and using a nasal saline spray to avoid dryness and crust formation leading to nasal bleeding and also help faster healing process. Additionally, a worm mist humidifier should be placed at bed site while patients sleep at home. Pain is extremely rare and over the counter pain medications are sufficient for most patients. Use of nasal decongestant for a long period of time has been one of the contributing factors for chronic turbinate hypertrophy as well as relapse of these types of surgery. Patients are strongly advised also to avoid smoking as it causes thickening of the overlying mucosa and increases relapse potentials. Finally nasal radioablation alone may have a minimal benefit for patients who suffer from obstructive apnea and we generally perform it as an adjunctive procedure with other surgical measures.

### **Soft palate surgeries**

In our opinion, one must first consider the most conservative treatments when planning to treat patients who suffer from snoring and sleep apnea. Besides nasal procedures described above, soft palate surgeries are the most commonly performed procedures today. Unfortunately, as mentioned earlier, depending on the site of the problem, the outcomes are variable. There are numerous methods available to address the soft palate, uvula and tonsils. The radioablation and other surgical procedures to stiffen the soft palate via injection of chemicals or synthetic substances and with all types of modifications have been promising but not stable in long run. We have seen an average failure or relapse amongst all available procedures and products to achieve volumetric reduction or vibration cession to be over 55%. Tongue-base radioablation surgeries, in our opinion, have been

the most disappointing procedures particularly, since they had the most relapse five years after the initial treatment.

The above statement holds true to the latest snoring treatment using Pillar™ system, or palatal implants. It is minimally invasive procedure that could be effective if patients are chosen appropriately for reduction of snoring. Three tiny woven inserts (implants) are placed in the soft palate to help reduce the vibration that causes snoring and the ability of the soft palate to obstruct the airway. Once in place, the inserts could add structural support to the soft palate in patients with small uvula and thick soft palate. Similar to radioablation patient selection could dictate the success or failure of these procedures. Patients who snore and are not obese and have low body mass index, with small sized uvula, tongue, and no tonsils benefit best from these procedures. The complications associated with Pillar™ implants were extrusion and infection. Also, the devices are expensive and the makers of the implants should consider revising the design possibly making the handle reusable and consider a detachable tip to reduce cost.

Traditional uvulopalatopharyngoplasty (UPPP) as well as our laser-assisted UPPP when combined with nasal radioablation on the other hand have been far more successful, although we have seen a range of 5 – 10% failure with these procedures as well. Overall, the UPPP can reduce snoring by an average of 70% but is only less than 50% effective in treating mild to moderate obstructive sleep apnea. The results were much better in patients who also lost weight, quit smoking and altered their dining habits.

In this article, we will describe our modification of UPPP using laser (LA-UPPP) as an office-based procedure. Although LA-UPPP is a commonly performed procedure, the readers must understand that no single procedure can be hailed as a cure for obstructive sleep apnea. With our best estimate the reduction of snoring intensity ranges following these procedures are between 50% and 70% while the rate of treatment benefit for obstructive sleep apnea is generally less than 50%.

A comprehensive health and snoring questioners is first provided to patient. Patient's oral and nasal cavity as well as pharyngeal areas are evaluated next. It is a well-known fact that the sound of snoring originates from various structures in the mouth, throat, and nose. Therefore, one

single procedure cannot address all sites of the problem. Once it is determined that patient could benefit from laser procedure a detailed discussion of LA-UPPP, its advantages, limitations and patient's expectations and potential benefits are discussed.

LA-UPPP is a single step, short, office-based procedure performed under intravenous (IV) sedation; the recovery is rapid. The parts of uvula between the two arches of posterior pillars as well as tonsils, when indicated or enlarged, are removed during this procedure.

### **Laser-assisted UPPP**

Although in past, these procedures were generally performed under local anesthesia, we now recommend IV sedation for all LA-UPPP procedures. Additionally, use of 20% benzocaine (Hurricane) is not recommended anymore, as the anesthetic effect of this spray may cause patients to aspirate blood or saliva and results in unnecessary complications. Our anesthetic method is as follow: following initiation of an IV line with a 20G angiocatheter in the antecubital fossa using dextrose water 5% or lactated Ringer's solution, 0.2 mg of robinol and 4 mg of dexamethasone (Decadron) are given IV. After about two minutes 50 mcg of fentanyl is administered which is followed by 3 – 5 mg of IV Versed. The next drug that is administered is 20 – 40 mg of propofol (Diprivan) for an average size adult. The patient is monitored at the same time with ECG, pulse oximetry, and blood pressure.

The most common local anesthetics used are lidocaine 2% with 1:100,000 epinephrine or marcaine 0.5% with 1:200,000 epinephrine. The anesthetics are injected in a semicircular fashion in the soft palate away from the site of incisions. The total amount of injection is approximately 1.8 to 3 mL. The excess amount of anesthetic solution in the areas may interfere with the function of carbon dioxide laser surgery and is not needed.

With patient sitting in the chair in a reclining position, a mouth prop and plastic double cheek retractor is placed in the mouth to give the best visualization and also protect the corners of the lip. The area of incision is marked with a surgical marking pen or by simply using Dr. Thompson's color transfer applicator available from most dental supply companies used commonly in prosthodontics. Following administration of anesthesia, a specialized pharyngeal handpiece with backstop is

used to initiate the ablation of the soft palate. The power setting of 12 – 15 W is normally sufficient with CO<sub>2</sub> laser and a straight laser tip. A lower power setting reduces the charred tissues formation, faster recovery and reduced pain. However, the speed of procedure could be reduced. We have modified our handpiece with an additional fiberoptic light to significantly enhance visualization of the surgical site.

Using a long curved Kelly the tip of the uvula is grabbed and pulled to one side. The laser ablation is then initiated on one side of the uvula as it is pulled gently towards the opposite side. This procedure is repeated on the opposite site and finally the uvula is released from its base attachment to the soft palate. Attention is directed to the posterior wall of the pharynx, to avoid touching the area with the laser back stopper, as extreme heat generated will cause tissue damage and may lead to nasopharyngeal adhesions.

The laser itself could in most cases control any bleedings encountered during the procedure. However, we strongly recommend placing sutures if the patient's airways are too narrow to expand the airway or if any bleeding was encountered. Chemical cauterization using silver nitrate should be avoided as this may lead to a temporary clot formation but a delayed bleeding. If the tonsils are excessively large, they can also be removed with the laser or electrocautery. It has been our experience that partial ablation of the tonsil within several weeks leads to significant reduction in the size of the tonsil and the tonsil in its entirety may not have to be removed. The tissue healing takes place three weeks after surgery and duration of the most intense pain is about 12 – 14 days.

### **Complications of CO<sub>2</sub> laser surgery**

In over 7,000 patients operated in our center, only 3% complications were noted. Severe sore throat is common in more than 70% of patients which lasts between 12 and 14 days. It responds to oral narcotic analgesics and a special combination of one-third antacid (Maalox), one-third diphenhydramine (Benadryl) and one-third lidocaine (known as magic mouth wash). Although patients have difficulty swallowing, they are encouraged to chew gum. The chance of bleeding particularly increases as the amount of dissection is increased in the lateral part of the soft palate and areas of the tonsillar pillars if a tonsillectomy is done at the same time as the

UPPP. As a general rule, we believe that any bleedings encountered during surgery necessitates placement of sutures to avoid delayed bleeding. We encountered about 9.5% bleeding incidences in over 7000 LA-UPPP operations performed over a 15-year period. In anticipation of tissue edema in the treated areas we recommend placing patients on oral steroid treatment with dexamethasone (Decadron) 4 mg for 4 days or Medrol dose pack.

Another common complaint patients may have is dryness at the back of throat, which is due to several factors but is primarily due to an expanded upper airway and fewer minor salivary glands. This sensation will gradually return. Feeling of tightness or lumpiness and foreign body sensations also could occur in about 5% of patients. This could be prevented by continued chewing gum, swallowing and raising the tongue to touch the roof of the mouth in such a way that the palatoglossus muscle is stretched and not allowed to scar down. A temporary swallowing difficulty has been noted in 11% of patients. However, none of our treated patients had developed fluid reflux (velopharyngeal insufficiency) or experienced voice changes and loss of taste. All patients were given antibiotics for five days period following LA-UPPP. A small number of patients (<5%) reported of having continued snoring after surgery.

It must be noted that the reported complication rates after traditional UPPP (performed in the operating room) include 20 – 60% postoperative nasal regurgitation although mostly on a temporary basis, 2 – 9% hemorrhage, and 0.5 – 10% velopharyngeal insufficiency and nasopharyngeal stenosis. There have been reports of seven patients who died following traditional UPPP in earliest cases operated in 1970's and 80's.<sup>37-40</sup> We believe however that these complications could be avoided by careful treatment planning and patient selection as well as improved technique.

### **Palatal radioablation**

The success of this procedure is based on several factors; first and foremost, is the patient selection. The abnormal anatomy, the location where the sound is generated from and patient's expectation and follow-up with additional treatments are amongst the other factors. Patients with excessively long and bulky uvula or severely hypertrophic soft palates with extremely narrow airway will not benefit from palatal radioablation for an extended time period. We noted a significant

relapse as much as 65% within two years of treatment in patients with elongated uvula who had a body mass index (BMI) of  $>27 \text{ kg/m}^2$ .

To perform palatal radioablation, the patient is brought into an outpatient office setting while blood pressure and other necessary monitors are attached. The best patient position is sitting in a dental chair. The system we describe here is the Coblation<sup>®</sup>. The Coblation<sup>®</sup> unit does not require any conductive pad but the other monopolar radiofrequency (RF) systems require a conductive pad placed on the lower back area. Topical anesthesia (benzocaine 20%) is applied to the palate and the patient is asked to swish that around the mouth for 30 sec. The topical anesthesia should reduce gagging and also any pain at the injection sites. Then, using a 27G or 30G dental needle, 2.5 – 3.0 mL of marcaine 0.5% with 1:200,000 epinephrine (or xylocaine 2% with 1:100,000 epinephrine) is injected at the junction of the hard and soft palate, continuing down and on the sides of the soft palate and the base of the uvula. Unlike the CO<sub>2</sub> laser, the RF procedures require an ample amount of local anesthesia to allow tissue expansion and better conduction of current to the area of the internal ablation.

The desired angle of the RF electrode is 35 – 45 degrees, depending on the anatomy of the hard and soft palate. Placement of the electrode is extremely important. The electrode is entered high in the soft palate so that the end point of the electrodes is just above the uvula but not in the uvula itself. To assure the proper placement of the electrode, it can be placed over the soft palate to clinically visualize the exact location and position of the electrode entry point prior to insertion. Care must also be taken to fully deploy the active component of the electrode into the patient's soft palate.

The patient has to be carefully monitored during the first 24 hours following the radioablation procedure. No postoperative antibiotics or narcotic pain medication is needed. Normally, patients experience a feeling of fullness in the back of their throat. Patients must be advised to sleep on a reclining chair or with the head elevated at a 45-degree angle for the first night after surgery. The soft palate and uvula will become edematous to a variable degree during the first 24 – 48 hours following the procedure. Usually, a minimal sore throat is noted after the procedure and an over-the-counter pain medication will be sufficient for pain management. The palatal

stiffening and volumetric reduction process takes 8 – 10 weeks and patients notice a change in the intensity of snoring, but there is no complete elimination of snoring after the first procedure. A second procedure is usually needed in severe snoring patients four months after the initial treatment.

Following palatal and nasal radioablation, snoring sound was reduced by an average of 30 – 40%. Improved nasal breathing was reported by 60% of patients. No incidences of major pain, nasal reflux, voice changes or bleeding were noted. Mucosal blanching was noted in 9% of patients but required no treatment. Patients with three or more lesions had a moderate amount of edema postoperatively; however, no treatment was needed. Although patients with the larger number of lesions had more edema immediately after the procedure, they showed much better results as far as the reduction of snoring and improved breathing 10 weeks following surgery. Patients with a short uvula and floppy soft palate respond best to this procedure. Unfortunately over 55% of the patients who underwent the radioablation procedures had relapse of the snoring and were additionally treated with laser. These patients experienced less post-operative pain as compared with the group that did not have the radioablation procedure done. However, more instant relief of snoring and significant improvement in nasal breathing and sleeping pattern was achieved. One of the major reasons for this change in our treatment modality was our limited knowledge of patient selection for these procedures. If a patient has a very large, edematous uvula and excessively hypertrophic soft palate, the LA-UPPP is the best treatment in our opinion. The success rate of RF is three times higher in women than men. This is mostly because of the anatomical differences we have observed in our female population. Subjectively, the snoring intensity reduction in the successful cases was over 68% on average; improved breathing and sleeping was 72%.

### **Palatal implants**

Following the initial success of the radioablation procedures, Pillar<sup>TM</sup> palatal implants (Restore Medical Incorporated St. Paul, MN) were introduced.<sup>41</sup> Patient selection and preparation is exactly as described above for radioablation. Once again placement of the implant probe is extremely important. It is entered high at the junction of hard

and soft palate making sure that the implant is not placed in the uvula itself. In order to assure the proper placement of the probe, it can be placed over the soft palate to clinically visualize the exact location and position of the electrode entry point prior to insertion. Determine insertion point and target zone for midline and lateral implant placements. At this point remove the transport lock (blue tab) by grasping the blue tab and pulling the lock away and out of the handle. Insert the needle through the mucosa layer into the muscle. Continue needle advancement in an arcing motion up to the full insertion depth marker. This marker needs to remain visible. Care must also be taken to fully deploy the active component of the electrode into the patient's soft palate. Ensure that the needle does not exit any portion of the soft palate and become exposed.

Unlock the slider by applying downward pressure to the arms of the lock just beneath the slider and the back of the handle. Begin deploying the implant by advancing the slider from the start position. Stop advancing the slider when it reaches the halfway deployment position. You may hear an audible "click" and receive tactile feedback indicating the halfway deployment position. Additionally, viewing the side of the delivery tool will indicate the slider position. Withdraw the needle until the halfway depth marker is visible. When the halfway depth marker on the needle is visible, continue advancing the slider until it comes to a stop at the full deployment position. When advancing the slider into the full deployment position, the contact of the implant with tissue at the distal end of the needle track may result in a feeling of resistance and naturally cause the needle tip to push up or out. After the implant is fully deployed, withdraw the needle from the palate following the insertion path (move the handle in an arcing fashion). Repeat procedure for lateral implants. The target distance between implants is approximately 2 mm. Inspect the needle insertion site. If a portion of the implant is exposed, it must be gently removed with forceps to mitigate the risk of infection or extrusion. Inspect the dorsal (nasal) surface of the soft palate. If the implant is visible, it must be removed.

Pillar implants in selected cases with short uvula, hyperplastic soft palate and BMI of <25 kg/m<sup>2</sup> with minimal indication of obstructive sleep apnea is an effective, simple method for reducing the snoring sound intensity. It is imperative that

surgical cases are selected meticulously for this procedure since the long-term results, in 50% of cases, in the author's experience, had relapse of their snoring problem and the effectiveness of this procedure for correcting the obstructive sleep apnea is highly questionable.

### **Injection snoreplasty**

The concept of injection snoreplasty is similar to the palatal radioablation.<sup>42</sup> Using the same protocol as other procedures performed under local anesthesia. Sotradecol® (Elkins-Sinn, Inc.) is a sterile nonpyrogenic solution for intravenous use as a sclerosing agent. It contains sodium tetradecyl sulfate, benzyl alcohol, and dibasic sodium phosphate. A test dose of 0.1 mL of sodium tetradecyl sulfate (Sotradecol® 1 – 3%) is initially injected into the soft palate to test for allergic reactions. If no side effect was noted, then deliver the rest of the solution (2 mL total doses) into the midline of the soft palate. Just like radioablation, the injection site could be modified to include two lateral injection sites on either side of the midline injection. About two minutes following the injection the area turns purple signifying the sclerosing agent is having an effect. Over the course of a few weeks, this leads to the development of scar tissue and palatal stiffening, which reduces the vibration of the soft palate, the main cause of snoring. Patients are sent home with a narcotic containing pain medication.

Although this procedure is inexpensive and seemingly simple, the outcome and complications could be unpredictable when compared with more controlled radioablation procedures. One area of concern for any practitioner who plans to use or is already using this agent for treatment of snoring is the safety issue of the off label use of Sotradecol®. It is recommended in the Physicians Desk Reference (PDR) that Sotradecol® is for IV use only such as for sclerotherapy of leg veins. It also states that there are possible side effects if the agent is injected non-intravenously. These include; severe local effects such as tissue necrosis; sloughing and necrosis after extravasation; allergic reactions including anaphylaxis. Four deaths have been reported with the use of Sotradecol®.

The long-term effect of this procedure is not yet known. However, in our extensive studies with radioablation, Somnoplasty, Coblation, and many other techniques, we believe that the effects are temporary and this procedure is effective in

selected patients who suffer from chronic snoring and are not obese or suffer from obstructive sleep apnea.

### **Tongue volumetric reduction**

As stated above, one of the main sites of obstruction of the upper airway is the base of the tongue collapsing in the pharynx. Any attempts to apply forward pressure on the tongue or reduce the amount of tongue volume to avoid posterior drop of the tongue will address the obstructive airway significantly. Computerized axial tomography has confirmed that tongue volume increases with increasing obesity. However, the tongue may be of normal size but appear larger than normal if the volume of the oral cavity is decreased because of retropositioned jaws. In our opinion radioablation of the tongue has been the most disappointing procedures amongst the various radiofrequency assisted volumetric reduction procedures. The concept, however, deserves careful analysis and further research. Of course, maxillomandibular advancements combined with genioplasty can address this issue in selected cases sufficiently. In some patients who could tolerate dental repositioning appliances also tongue is positioned in a more favorable location. However, the base of the tongue radioablation results are not permanent and there is significant possibility of relapse particularly as patients age or gain weight.

Another procedure that has been advocated for over 30 years is partial glossectomy, removing the anterior and a portion of the middle third of the tongue. Taste and sensation are minimally affected after surgery.

### **Tonsillectomy**

Our tonsils are three masses of tissue: the lingual tonsil, the pharyngeal (adenoid) tonsil, and the palatine or fascial tonsil. The tonsils are lymphoid tissue covered by respiratory epithelium, which is invaginated and which produces tonsillar crypts. In addition to producing lymphocytes, the tonsils are active in the synthesis of immunoglobulins. Although healthy tonsils offer immune protection, diseased tonsils are less effective at serving their immune functions. Diseased tonsils are associated with decreased antigen transport, decreased antibody production above baseline levels, and chronic bacterial infection.

Although at much lower rate than 1950's,

**Table 3.** Summarizing our experience with various procedures during last 15 years of treating patients who suffered from severe snoring and/or obstructive sleep apnea. The important column is the one on the right side where the relative frequencies of relapse with various techniques are shown.

Procedure	Initial effectiveness	Total No. of patients	% of relapse or failure
Laser assisted palatoplasty (LAUP)	75%	980	50% May cause narrowing of the airway in long run
Laser assisted uvulopalatopharyngoplasty (LA-UPPP)	75%	7024	25 – 35% (14 years) Weight gain related
ultrasound assisted uvulopalatopharyngoplasty (UA-UPPP)	75%	56	25 – 35% (8 years) Weight gain related
Partial /Total tonsillectomy (In office)	100% Obstructive +/- or inflamed tonsils	382	0%
Pillar Implants (Palatal polyester implants)	50 – 75% In selected patients	35	60% Up to 3 years post-op Ineffective for OSA
Palatal radioablation (RA)	40 – 75% In selected patients	560 Somnus/ Coblation/ Elman	60% (9 years)
Nasal radioablation Nasal (RA)	25 – 75% Nasal snoring and chronic congestion	3,200 Somnus/ Coblation/ Elman	30% (9 years)
Tonsillar radioablation (RA)	85% Obstructive tonsils	156 Somnus/ Coblation/ Elman	20% (6 years)
Tongue base RA	75% OSA	18 Somnus	75% (7 years)
Injection snoreplasty	50% In selected patients	12 Sotradecol (Sulfate sclerosing agent)	90% 5 years

tonsillectomy is still an extremely common operation and considered the most common major surgical procedure performed in children. This procedure is still surrounded by controversy, especially regarding indications for surgery and details of surgical technique.<sup>43</sup> In general there are several criteria needed for tonsillectomy. We can categorize them as absolute indications for tonsillectomy such as:

- Obstructive tonsils — one of the leading causes of upper airway obstruction in obstructive sleep apnea cases.
- Chronic infection (peritonsillar abscess) or frequent tonsillitis, which is unresponsive to medical management and drainage or causes the patient to develop febrile convulsion.
- If a biopsy or total excision is required due to presence of pathology.

There are other situations that are considered relative indications for tonsillectomy such as:

- Three or more tonsil infections per year despite adequate medical therapy.
- Persistent foul taste or breath due to chronic tonsillitis that is not responsive to medical therapy.

### Tonsillar coblation channeling

Treatment for volumetric reduction of tonsils is performed in an outpatient setting and under a light IV sedation.<sup>44</sup> Patients are prophylactically treated with appropriate antibiotics several days prior to the procedure. Assurances are made that there are no active tonsillar infection. The Coblation® reflux wand 55 is used for tonsillar channeling radioablation. It comes prebent and only needs to be dipped in saline gel as its conductive medium. The unit is generally set at #6 and the probe is kept in place for 15 seconds. Excessive heat will cause mucosal erosion and ulceration. The wand is inserted into the enlarged tonsil in three to five locations. Patient experiences minimal discomfort following the treatment. Within 4 – 6 weeks following the procedure, the tonsillar size reduction is recorded and the minimal reduction after the first treatment is generally 60%. Postoperative pain is generally minimal and potential for bleeding and other complications are significantly less than traditional tonsillectomy. Patient is kept on oral antibiotics for 10 days and chlorohexidine mouth rinse for two months after surgery. The effectiveness of this procedure alone

for treatment of obstructive sleep apnea needs to be studied further.

### Conclusions

No single surgical technique will adequately correct all symptoms of snoring and obstructive sleep apnea as they are caused by various factors. In this article, we have shared our techniques and experiences and the final chart illustrates our results Table 3. Obstructive sleep apnea is a fascinating medical condition for any surgeons to study and comprehend before starting to attempt its treatment. Snoring treatments are also complex and challenging as well. In many instances patient or their bed partner's expectation may not be realistic and our role is to educate them all. Otolaryngologists, dental practitioners and particularly oral and maxillofacial surgeons are important members of the team of professionals that could effectively diagnose, make a treatment plan, and manage patients who suffer from these ailments. Obstructive sleep apnea is a common condition particularly in the developed countries where obesity is more rampant and it is associated with significant morbidity and mortality. Our knowledge of the pathophysiology of the airway places us amongst the most knowledgeable professionals in the field. We can identify anatomic abnormalities in the oral cavity both soft tissue and hard tissue and have the knowledge and ability to offer orthognathic surgeries, laser, radiofrequency and even mandibular advancement appliances if we deemed them helpful.

### References

- World Health Organization, EIP/KMS/LNK. Avenue Appia 20, 1211 Geneva 27, Switzerland, (fact sheets 2007). Available from: URL: <http://www.who.int/mediacentre/factsheets/fs311/en/>.
- Parkin DM, Bray F, Ferlay J, Pisani P. Global cancer statistics, 2002. *CA Cancer J Clin*. 2005; **55**: 74 – 108.
- Malekzadeh R, Mohamadnejad M, Merat S, Pourshams A, Etemadi A. Obesity pandemic: an Iranian perspective. *Arch Iranian Med*. 2005; **8**: 1 – 7.
- Bahrami H, Sadatsafavi M, Pourshams A, Kamangar F, Nouraei M, Semnani S, et al. Obesity and hypertension in an Iranian cohort study; Iranian women experience higher rates of obesity and hypertension than American women. *BMC Public Health*. 2006; **6**: 158.
- Scharf MB. Sleep disorders. In: Paparella MM, Shumrick DA, Gluckman JL, Meyerhoff WL, eds. *Otolaryngology*. 3rd ed. Philadelphia: Harcourt Brace Jovanovich, Inc; 1991: 865 – 877.
- Thawley SE. Sleep apnea disorders. In: Cummings CE, ed. *Otolaryngology-Head and Neck Surgery*. 2nd ed. St. Louis: Mosby-Year Book, Inc; 1993: 1392 – 1413.
- Poole MD. Obstructive sleep apnea. In: Bailey BJ, ed. *Head and Neck Surgery—Otolaryngology*. Philadelphia: JB Lippincott Co.; 1993: 598 – 611.
- Bixler EO, Vgontzas AN, Lin HM, Ten Have T, Rein J, Vela-Bueno A, et al. Prevalence of sleep-disordered breathing in women: effects of gender. *Am J Respir Crit Care Med*. 2001; **163**: 608 – 613
- Dancey DR, Hanly PJ, Soong C, Lee B, Shepard J Jr, Hoffstein V. Gender differences in sleep apnea: the role of neck circumference. *Chest*. 2003; **123**: 1544 – 1550.
- Davies RJ, Stradling JR. The relationship between neck circumference, radiographic pharyngeal anatomy, and the obstructive sleep apnea syndrome. *Eur Respir J*. 1990; **3**: 509 – 514.
- Metes A, Hoffstein V, Anderson D. Site of airway obstruction in patients with obstructive sleep apnea before and after uvulopalatoplasty. *Laryngoscope*. 1991; **101**: 1102 – 1108.
- Chaban R, Cole P, Hoffstein V. Site of the upper airway obstruction in patients with obstructive sleep apnea. *Laryngoscope*. 1998; **98**: 641 – 647.
- Hudgel DW, Hendricks C. Palate and hypopharynx--sites of inspiratory narrowing of the upper airway during sleep. *Am Rev Resp Dis*. 1988; **138**: 1542 – 1547.
- Isono S, Remmers JE, Tanaka A, Sho Y, Sato J, Nishino T. Anatomy of pharynx in patients with obstructive sleep apnea and in normal subjects. *J Appl Physiol*. 1997; **82**: 1319 – 1326.
- Strelzow VV, Blanks RHI, Basile A, Strelzow AE. Cephalometric airway analysis in obstructive sleep apnea syndrome. *Laryngoscope*. 1988; **98**: 1149 – 1158.
- Naganuma H, Okamoto M, Woodson BT, Hirose H. Cephalometric and fiberoptic evaluation as a case-selection technique for obstructive sleep apnea syndrome (OSAS). *Acta Otolaryngol Suppl*. 2002; **547**: 57 – 63.
- Riley RW, Powell NB. Maxillofacial surgery and obstructive sleep apnea syndrome. In: Koopman CF, Moran WB, eds. *The Otolaryngologic Clinics of North America*. 1990; **23**: 809 – 826.
- Riley RW, Powell NB, Guilleminault C. Inferior sagittal osteotomy of the mandible with hyoid myotomy-suspension: a new procedure for obstructive sleep apnea. *Otolaryngol Head Neck Surg*. 1986; **94**: 589 – 593.
- Finkelstein Y, Shapiro-Feinberg M, Stein G, Ophir D. Uvulopalatopharyngoplasty vs. laser-assisted uvulopalatoplasty: anatomical considerations. *Arch Otolaryngol Head Neck Surg*. 1997; **123**: 265 – 276.
- Woodson BT, Steward DL, Weaver EM, Javaheri S. A randomized trial of temperature-controlled radiofrequency, continuous positive airway pressure, and placebo for obstructive sleep apnea syndrome. *Otolaryngol Head Neck Surg*. 2003; **128**: 848 – 861
- Powell NB. Radiofrequency volumetric reduction of the tongue. A porcine pilot study for the treatment of obstructive sleep apnea syndrome. *Chest*. 1997; **111**: 1348 – 1355.
- Madani M. Complications of laser assisted uvulopalatopharyngoplasty (LA-UPPP) and radiofrequency treatments of snoring and chronic nasal congestion; a 10 year review of 5600 patients. *J Oral Maxillofac Surg*. 2004; **62**: 1351 – 1362.
- Madani M. Surgical treatment of snoring and mild sleep apnea. *Oral Maxillofacial Surg Clin N Am*. 2002; **14**: 333 – 350.

- 24 Ikematsu T. Study of snoring 4<sup>th</sup> report: therapy. *J Jpn Otol Rhin Laryngol.* 1964; **64**: 434 – 435.
- 25 Fujita S, Conway W, Zorick F, Roth T. Surgical correction of anatomic abnormalities in obstructive sleep apnea syndrome: uvulopalatopharyngoplasty. *Otolaryngol Head Neck Surg.* 1981; **89**: 923 – 934.
- 26 Conway W, Fujita S, Zorick F, Sickelsteel J, Roehrs T, Wittig R, et al. Uvulopalatopharyngoplasty: one-year follow-up. *Chest.* 1985; **88**: 385 – 387.
- 27 Koay CB, Freeland AP, Stradling JR. Short- and long-term outcomes of uvulopalatopharyngoplasty for snoring. *Clin Otolaryngol.* 1995; **20**: 45 – 48.
- 28 Wright S, Haight J. Changes in pharyngeal properties after uvulopalatopharyngoplasty. *Laryngoscope.* 1989; **99**: 62 – 65.
- 29 Haavisto L, Suopaa J. Complications of uvulopalatopharyngoplasty. *Clin Otolaryngol.* 1994; **18**: 43 – 247.
- 30 Wareing MJ, Callan VP. Laser assisted uvulopalatoplasty: six and eighteen month results. *J Laryngol Otol.* 1998; **112**: 639 – 641.
- 31 Kamami YV. Laser CO2 for snoring: preliminary results. *Acta Otorhinolaryngol Belg.* 1990; **44**: 451 – 456.
- 32 Coleman JA Jr. Laser-assisted uvulopalatoplasty: long-term results with a treatment for snoring. *Ear Nose Throat J.* 1998; **77**: 22 – 24, 26 – 29, 32 – 34.
- 33 Krespi YP, Pearlman SJ, Keidar A. Laser assisted uvulopalatoplasty for the treatment of snoring. *J Otolaryngol.* 1994; **23**: 328 – 334.
- 34 Krespi YP, Keidar A, Khosh MM. The efficacy of laser-assisted uvulopalatoplasty in the management of obstructive sleep apnea and upper airway resistance syndrome. *Operative Techniques in Otolaryngology-Head Neck Surgery.* 1994; **5**: 235-43
- 35 Carenfelt C. Laser uvulopalatoplasty in treatment of habitual snoring. *Ann Otol Rhinol Laryngol.* 1991; **100**: 451 – 454.
- 36 Madani M. Nasal turbinate somnoplasty utilization of radiofrequency to treat chronic nasal obstruction and congestion. *Br J Oral and Maxillofac Surg.* 1999; **37**: 414 – 415.
- 37 Carenfelt C, Haraldsson PO. Frequency of complications after uvulopalatopharyngoplasty. *Lancet.* 1993; **341**: 437.
- 38 Croft CB, Golding Wood DG. Uses and complications of uvulopalatopharyngoplasty. *J Laryngol OTO.* 1990; **104**: 871 – 75.
- 39 Esclamando R, Glenn M. Perioperative complications and risk factors in the surgical treatment of obstructive sleep apnea syndrome. *Laryngoscope.* 1989; **99**: 1125 – 1129.
- 40 Fairbanks DN. Uvulopalatopharyngoplasty complications and avoidance strategies. *Otolaryngol Head Neck Surg.* 1990; **102**: 239 – 245.
- 41 Ho WK, Wei WI, Chung KF. Managing disturbing snoring with palatal implant. *Arch Otolaryngol Head Neck Surg.* 2004; **130**: 753 – 758.
- 42 Brietzke S, Mair E. Injection snoreplasty: how to treat snoring without all the pain and expense. *Otolaryngol Head Neck Surg.* 2001; **124**: 503 – 510.
- 43 Pizzuto MP, Brodsky L, Duffy L, Gendler J, Nauenberg E. A comparison of microbipolar cautery dissection to hot knife and cold knife cautery tonsillectomy. *Int J Pediatr Otorhinolaryngol.* 2000; **52**: 239 – 246.
- 44 Madani M. Tonsillar ablation, using radiofrequency for reduction of tonsils. *Otolaryngol Head Neck Surg.* 2000; **123**: 163.