
Case Report

Metastatic Carcinoma of the Ovary Presenting as Zosteriform Lesions

Abbas Rasi MD*, Leila Tajziehchi MD*, Nasrin Shaiianfar MD**

Distant metastases are unusual at presentation and during the course of ovarian carcinoma. Skin metastases may be the first presenting sign of metastatic carcinoma of the ovary. Ovarian epithelial adenocarcinoma rarely metastasizes to the skin, and can be seen in less than 4% of patients. It usually presents as subcutaneous nodules and, less commonly, as inflammatory metastases, which mimic viral or bacterial skin infections. The histology in most of the tumors is serous papillary adenocarcinoma (grade 1 or 2). The prognosis in most patients is poor, thus palliative treatment is usually indicated. We report a patient with widespread skin metastases and review the literature on this rare presentation.

Archives of Iranian Medicine, Volume 10, Number 2, 2007: 250 – 252.

Keywords: Distant metastases • ovarian carcinoma • skin metastases

Introduction

Cutaneous metastases represent spread of a preexisting malignancy to the skin. They have diagnostic importance because, in addition to signifying poor prognosis, they may be the first manifestation of undiscovered malignancy. Distant metastases are unusual at presentation and during the course of ovarian carcinoma. Skin metastases may be the first presenting sign of metastatic carcinoma of the ovary.¹ The clinical appearance of skin metastases is usually not distinctive. They may resemble the primary tumor in color and consistency and vary in size up to several centimeters. The prognosis is poor with a median survival of four months; however, in selected cases integrated multimodality treatment may result in a palliation of the symptomatology and even in a prolonged survival.²

Herein, we report a patient with widespread skin metastases and review the literature.

Case Report

A 60-year-old Iranian woman was in good health until March 2003, when she developed an enlarged, solitary right groin lymph node. Histopathological examination revealed a poorly differentiated metastatic adenocarcinoma.

Computed tomography of the abdomen and pelvis showed evidence of multiple bilateral ovarian lesions less than 2 cm in diameter. Some lesions demonstrated enhancement suggesting that they were solid masses. The patient refused surgical treatment. So, combination chemotherapy with cisplatin and paclitaxel (Taxol) was started. Eighteen months later she developed cutaneous lesions and presented to the dermatology department. Physical examination showed lymphedema of the right leg, right inguinal lymphadenopathy, numerous asymptomatic erythematous papules with vesicular appearance, and ulcerative and crusted firm to hard nodules (0.5 – 2 cm in diameter) over the lower aspect of the abdominal skin and the upper part of the right lower extremity (Figure 1). No mucous membrane or discrete acral lesions were noted. Biopsy of the lesions showed multiple lymphatic spaces in the dermis infiltrated by metastatic adenocarcinoma consistent with metastatic adenocarcinoma of the ovary (Figure 2). A chest radiograph revealed no

Authors' affiliations: *Department of Dermatology, **Department of Pathology, Iran University of Medical Sciences, Tehran, Iran.

•Corresponding author and reprints: Abbas Rasi MD, Department of Dermatology, Hazrat-e Rasol Hospital, Niayesh St., Sattarkhan Ave., Tehran, Iran.

Tel: +98-216-651-5001-9, Fax: +98-216-651-7118,

E-mail: dr_rasi2002@yahoo.com.

Accepted for publication: 13 September 2006

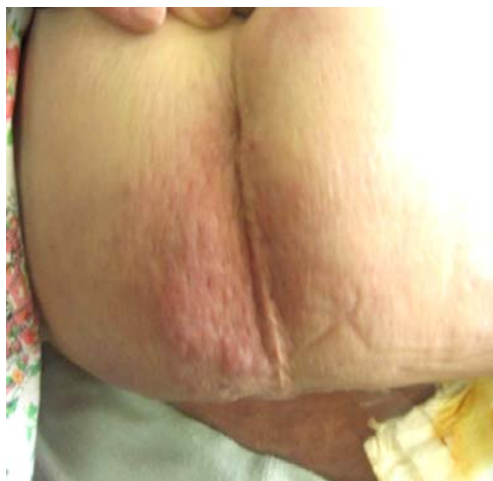

Figure 1. Skin lesions of metastatic adenocarcinoma of the ovary.

abnormality. Computed tomography and magnetic resonance imaging of the liver, spleen, and other organs were normal. The patient received combination chemotherapy with cisplatin and paclitaxel, but she did not improve and died about one month later.

Discussion

Ovarian carcinoma is the most common cause of death due to gynecologic malignancies in

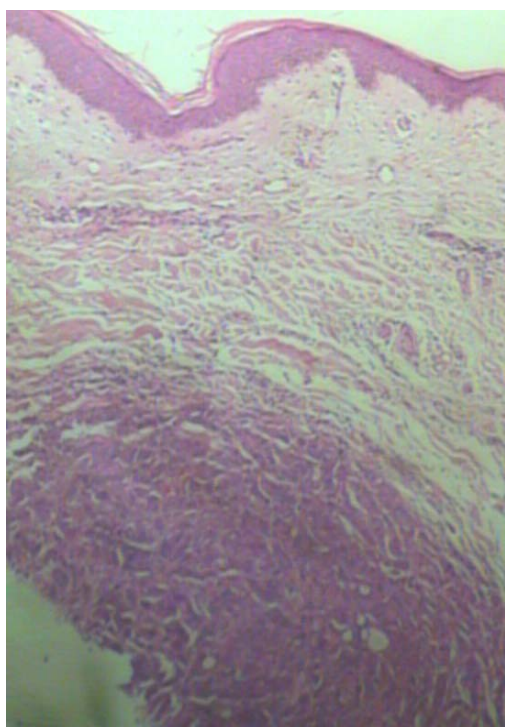


Figure 2. Histology: Multiple lymphatic spaces in the dermis infiltrated by metastatic adenocarcinoma (H & E, ×40).

Europe and the United States.³ The disease usually remains confined to the peritoneal cavity at the presentation and throughout its course in approximately 85% of the patients.⁴

Several mechanisms for pathogenesis of cutaneous metastasis have been proposed; direct spread from the underlying growth, accidental implantation following surgery, and contiguous spread of tumor cells through the lymphatics. The most common mode of spread of ovarian carcinoma to the skin is retrograde, from involved proximal lymph nodes.⁵⁻¹⁰

In our case, the most likely mechanism was contiguous extension of tumor cells through the lymphatics. The presence of right side inguinal lymphadenopathy and lymphedema could explain this phenomenon. Skin involvement in our patient was characterized by a dermatomal pattern.

Distant metastases seldom occur in the absence of intraabdominal disease.¹¹ Data from the literature concerning distant metastasis in ovarian carcinoma is scarce. The most common sites for distant metastasis are pleura, liver, lung, and lymph nodes. Skin metastasis occurs in 2 – 3.5% of patients with ovarian carcinoma.¹²⁻¹⁴ The skin metastases of the ovarian carcinoma are almost always at the abdominal wall skin. Other sites of skin metastases are chest wall, breast, and buttocks.¹⁴

The clinical appearance of skin metastases is usually not distinctive. They may resemble the primary tumor in color and consistency and vary in size up to several centimeters. There are several clinical presentations of skin metastases originating from epithelial ovarian carcinoma such as isolated cutaneous nodule, multiple cutaneous nodules, ulcers, inflammatory lesions, herpetiform, sclerotic, and blistered lesions, and cicatricial plaques. On rare occasions, the metastases may be zosteriform in appearance or may resemble erythema annular, a chancre, an epidermal cyst, and a condyloma.¹³⁻¹⁵ Most cases present with an abdominal cutaneous nodule, usually located near or in the scar of the prior disease-oriented surgical intervention.^{1,16}

Metastasis to skin generally shows histological resemblance to those of the primary tumor. The pattern is usually a well-differentiated adenocarcinoma, sometimes having a papillary configuration with psammoma bodies. Metastases are centered in the dermis, although there is sometimes extension into the subcutis. The

epidermis is usually intact, and there is an underlying narrow zone of compressed collagen separating the tumor from the epidermis (grenz zone). Typically, the histology of inflammatory metastases demonstrates the presence of tumor cells in the subepidermal lymphatic vessels. This causes obstruction, lymphedema, and erythema, which can mimic bacterial cellulitis or lymphangitis.

Skin metastases from ovarian carcinoma typically occur in advanced disease with widespread peritoneal involvement, and indicate a poor prognosis.¹⁷ The most important prognostic factor associated with survival is the interval between the diagnosis of ovarian cancer and the cutaneous involvement.¹¹ Overall survival after diagnosis of skin metastasis from ovarian carcinoma is between four and twelve months, but there are few patients who have survived for many years after the diagnosis.¹⁴

Metastatic ovarian carcinoma represents a difficult problem for the clinician because of its unsatisfactory response to conventional treatments.¹⁸ Because the skin metastasis is invariably accompanied by a widespread intraperitoneal involvement, the main approach to the patient should be based on the control of abdominal disease. For the local cutaneous disease, surgical resection should be considered.² For extensive cutaneous metastases, electrocoagulation has been successfully used for local control of pain, hemorrhage, and infection, while surgical excision may be impractical.¹⁴ Electron beam therapy has been applied when large areas of skin require radiation therapy, as has photodynamic therapy.¹⁹ The latter two methods may provide excellent control of local cutaneous disease but can not deal with systemic disease.

Although cutaneous metastases from ovarian carcinoma are rare, especially without peritoneal disease, physicians should be aware that ovarian carcinoma is not a disease that remains confined to the abdomen and pelvis, and any atypical rash should be biopsied.

References

- 1 Brownstein MH, Helwig EB. Spread of tumors to the skin. *Arch Dermatol.* 1973; **107**: 80 – 86.
- 2 Cormio G, Capotorto M, Vagno GD, Cazzolla A, Carriero C, Selvaggi L. Skin metastases in ovarian carcinoma: a report of nine cases and a review of the literature. *Gynecol Oncol.* 2003; **90**: 682 – 685.
- 3 Wingo PA, Tong T, Bolden S. Cancer statistics. *CA Cancer J Clin.* 1995; **45**: 8 – 30.
- 4 Ansell SM, Rapoport BL, Falkson G, Raats JI, Moeken CM. Survival determinations in patients with advanced ovarian cancer. *Gynecol Oncol.* 1993; **50**: 215 – 220.
- 5 Rose PG, Piver MS, Tsukada Y, Lau TS. Metastatic patterns in histologic variants of ovarian cancer. An autopsy study. *Cancer.* 1989; **64**: 1508 – 1513.
- 6 West EA, White SI, Sidky K, Green JA. An unusual distribution of cutaneous metastases of ovarian carcinoma. *Clin Exp Dermatol.* 2005; **30**: 440 – 441.
- 7 Spencer PS, Helm TN. Skin metastases in cancer patients. *Cutis.* 1987; **39**: 119 – 121.
- 8 Tharakaram S. Metastases to the skin. *Int J Dermatol.* 1988; **27**: 240 – 242.
- 9 Krumerman M, Garret R. Carcinoma metastatic to skin. *NY State J Med.* 1977; **77**: 1900 – 1903.
- 10 Brownstein MH, Helwig EB. Patterns of cutaneous metastasis. *Arch Dermatol.* 1972; **105**: 862 – 868.
- 11 Cormio G, Rossi C, Cazzolla A, Resta L, Loverro G, Greco P, Selvaggi L. Distant metastases in ovarian carcinoma. *Int J Gynecol Cancer.* 2003; **13**: 125 – 129.
- 12 Dauplat J, Hacker NF, Nieberg RK, Berek JS, Rose TP, Sagae S. Distant metastases in epithelial ovarian carcinoma. *Cancer.* 1987; **60**: 1561 – 1566.
- 13 Schonmann R, Altaras M, Biron T, Bernheim G, Fishman A. Inflammatory skin metastases from ovarian carcinoma--a case report and review of the literature. *Gynecol Oncol.* 2003; **90**: 670 – 672.
- 14 Yilmaz Z, Bese T, Demirkiran F, Ilvan S, Sanioglu C, Arvas M, et al. Skin metastases in ovarian carcinoma. *Int J Gynecol Cancer.* 2006; **16 (suppl 1)**: 414 – 418
- 15 Kikuchi Y, Matsuyama A, Nomura K. Zosteriform metastatic skin cancer: report of three cases and review of the literature. *Dermatology.* 2001; **202**: 336 – 338.
- 16 Merimsky O, Chaitchik S, Inbar M. Skin metastases of ovarian cancer: report of three cases. *Tumori.* 1991; **77**: 268 – 270.
- 17 Graham RM, Cox NH. Systemic disease and the skin. In: Burns T, Breathnach S, Cox N, Griffiths C, eds. *Rook's Textbook of Dermatology.* 7th ed. Oxford: Blackwell Science; 2004.
- 18 Cormio G, Maneo A, Parma G, Pittelli MR, Miceli MD, Bonazzi C. Central nervous system metastases in patients with ovarian carcinoma. A report of 23 cases and a literature review. *Ann Oncol.* 1995; **6**: 571 – 574.
- 19 Tapley ND. Radiation therapy with electron beam for skin metastases. *Semin Oncol.* 1981; **8**: 49 – 58.