

---

## Case Report

---

### Actinomycosis of the Tongue

Ataollah Habibi DDS MSc\*, Jahanshah Salehinejad DMD MSc\*\*, Shadi Saghafi DMD MSc\*\*,  
Ehsan Mellati DDS\*\*\*, Mehdi Habibi DDS\*\*\*

---

**Actinomycotic infections are known to be associated with difficulties in making the diagnosis and treatment. Actinomycosis of the tongue is rare and of great importance, not only because it can mimic many other diseases, but also because the tongue itself has some histophysiological features that make it resistant to infections. In this report, we present a case of lingual actinomycosis and discuss the predisposing factors as well as the diagnostic methods and therapeutic modalities.**

*Archives of Iranian Medicine, Volume 11, Number 5, 2008: 566 – 568.*

---

**Keywords:** Actinomycosis • oral infections • tongue

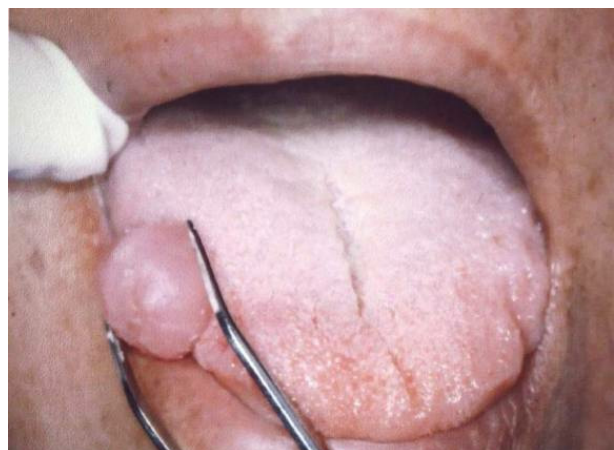
#### Introduction

Actinomycosis was first described in 1877, and its pathogenesis in humans was reported in 1885. It is a chronic suppurative infection mainly caused by *Actinomyces israelii*, although other types such as *A. naeslundii*, *odontolyticus*, or *viscosus* are found. It is a Gram-positive anaerobic bacterium that is hardly cultivable. This commensal microorganism exists independently in nature, and thus the origin of the illness is almost always endogenous. It can be isolated from the mouth, tonsil, and the gastrointestinal (GI) tract; the anaerobic type which is responsible for human infection lives in the mouth.<sup>1,2</sup>

#### Case Report

A 54-year-old woman presented to the Department of Oral and Maxillofacial Surgery of Mashhad School of Dentistry complaining of a mass on the right border of her tongue which

appeared following a tongue bite few months before and had recently grown. The patient's past dental history, medical history, and family history was insignificant. Intraoral examination revealed an elevated nonulcerated and almost nontender mass covered with normal mucosa (Figure 1). No restriction of the tongue movement was found. There was no cervical lymphadenopathy and the laboratory data were unremarkable. Under local analgesia, excisional biopsy of the mass was performed. The mass was 12×16 mm in diameter, well-demarcated, and relatively soft. Histologically, a granulomatous inflammatory lesion with abscess formation including large collections of polymorphonuclear leukocytes was seen. In addition, colonies of actinomycetes



**Figure 1.** Front view of the mass, located on the right border, in the anterior two-thirds of the tongue.

---

**Authors' affiliations:** \*Department of Oral and Maxillofacial Surgery, \*\*Department of Oral and Maxillofacial Pathology, \*\*\*Mashhad Center for Dental Research, School of Dentistry, Mashhad University of Medical Sciences, Mashhad, Iran.

**Corresponding author and reprints:** Ataollah Habibi DDS MSc, Department of Oral and Maxillofacial Surgery, School of Dentistry and Dental Research Center, Vakilabad Blvd., Mashhad, Iran.

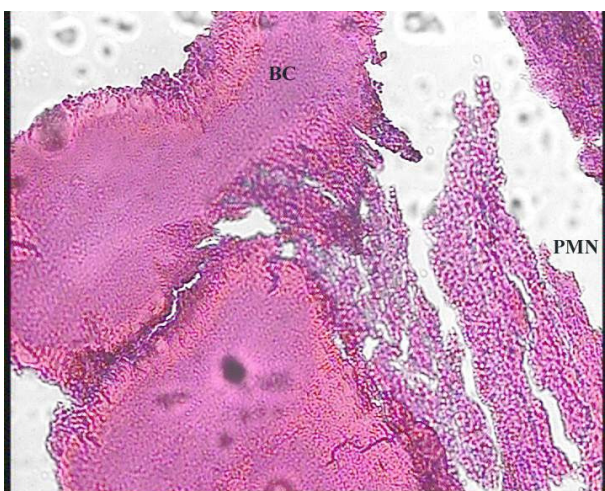
Tel: +98-511-882-9501, Fax: +98-511-882-9500,  
E-mail: dr.atabibibi@gmail.com

Accepted for publication: 1 October 2007

consisting of club-shaped filaments were apparent in histologic examination (Figure 2). After biopsy, treatment with intravenous penicillin was commenced and continued for three weeks. The patient was instructed and encouraged to keep a better oral hygiene and was advised to return for occasional follow-ups. Follow-up visits after one month, three months, and one year revealed no evidence of recurrence.

## Discussion

Oral actinomycosis, although not common, is an important entity to the cervicofacial clinicians. Presenting clinical manifestations are often confusing because they usually resemble other disease processes.<sup>1</sup> The usual pattern of the disease is the multiple abscess formation and the most common symptoms are swelling and hardening of the soft tissue. Actinomycosis produces a massive fibrotic reaction surrounding the necrotic center of the lesion, and thus, palpation often reveals a swelling of woody consistency.<sup>2</sup> Because clinical symptoms are nonspecific, actinomycosis can be readily misdiagnosed as a tumor. Although it is mentioned in the literature that untreated actinomycosis may involve the bone in 15% of the cases with a gradual cortical erosion,<sup>3</sup> unfortunately, most imaging techniques do not provide a significant help in diagnosis.<sup>2</sup> However, they can assist the clinician to define the lesion's inflammatory origin and differentiate it from neoplasms. More than 50% of the patients initially



**Figure 2.** Microscopic view demonstrating the large collections of polymorphonuclear leukocytes (PMN) as well as the bacterial colony (BC). The basophilic central core and the eosinophilic peripheral portion of the colonies are also apparent (H&E, original magnification  $\times 100$ ).

present with a slight hyperpyrexia, yet the presence of regional lymphadenopathy is not frequent, except in late stages of the disease.<sup>2</sup>

Lingual actinomycosis is rare, representing less than three percent of all reported cases of actinomycosis.<sup>4</sup> In 1989, Brignall and Gilhooly published a 20-year review of the English literature and found just seven cases.<sup>4</sup> In 2006, Atespare et al. reported that the overall number of reported cases does not exceed 15.<sup>5</sup> Its rarity can be explained by the fact that the histophysiological characteristics of the tongue make it resistant to infection. Its keratinized mucosal lining, richly vascular parenchyma, great mobility, and mechanical cleansing by saliva make it difficult for bacteria to adhere and multiply; thus, there are very few reports of tongue abscesses.<sup>5</sup> Tongue actinomycosis is generally located on the anterior two-thirds, lateral to the median sulcus, and presents as a moderately painful nodule set deep in the extrinsic and intrinsic muscles and poorly mobile on the adjacent planes.<sup>6</sup> Usually the patient is initially seen complaining of a painful tongue mass together with dysphagia, while there is a variable history of trauma.<sup>1</sup> However, unlike the previously reported pattern, our patient had a relatively soft and nontender mass without symptoms of dysphagia.

The differential diagnosis of tongue actinomycosis includes other infections (e.g., lingual abscess, nocardiosis, and botryomycosis) and neoplasms (e.g., granular cell tumor, neuroma, neurilemoma, lymphangioma, hemangioma, sarcoma, and metastatic tumors).<sup>4,7</sup> A presumptive diagnosis can be made based on the identification of the so-called "sulfur granules" in specimens obtained from chronic sinus tract, needle aspirates, or in biopsied tissues.<sup>8</sup> However, if doubt remains in the interpretation of the examined specimen, it can particularly be useful to culture the infected material on heart-brain agar or blood agar plates.<sup>9</sup> A more reliable technique to demonstrate the presence of actinomycosis using a fluorescent antibody has been described by Happonen and Viander.<sup>10</sup>

The pathogenesis of actinomycosis is not completely clear. The organism is unable to penetrate healthy tissue. To become invasive, it requires mucosal breakage to gain access to the submucosal tissue. Thereafter, it destroys local tissue in a highly vascularized and anaerobic region and replaces it with granulation tissue. Lesions of the bone and soft tissues may also show

multiple abscess formation which has little tendency to heal and may extend to the surface forming a sinus tract.<sup>9</sup> The yellowish purulent discharge from the chronic lesion may contain sulfur granules which represent colonies of the bacteria. The consensus is that trauma plays an important role in most cases, initiating the portal of entry for the organism.<sup>1</sup> We confirmed this hypothesis, because our case reported a history of a tongue bite shortly prior to the appearance of the lesion. In addition, poor oral hygiene and periodontitis may facilitate the penetration and pathogenesis of the microorganism.<sup>11</sup>

Once the diagnosis is established, treatment of actinomycosis consisting of prolonged administration of antibiotics with surgical excision or incision and drainage should be commenced as soon as possible. Penicillin is still the drug of choice in the treatment of nonallergic patients. Other therapies include administration of clindamycin, erythromycin, tetracycline, and lincomycin.<sup>12</sup> Sakallioğlu et al. proposed administration of doxycycline for those with gingival and periodontal involvement.<sup>11</sup> The recovery rate is approximately 90%.<sup>13</sup> This is because the lesions are amenable to surgery and antibiotic therapy. However, actinomycosis can recur after months or years of apparent cure,<sup>14</sup> and the reason for the prolonged antibiotic therapy is to prevent the chance of recurrence. It is therefore of primary importance to follow patients.

In summary, although cervicofacial actinomycosis is known to be the most common type, localized intraoral lesions occur rarely. An initial clinical examination can easily mistake the mass for a pyogenic abscess formation or benign or malignant neoplasia, and therefore, may lead to inappropriate or inadequate treatment. Due to the opportunistic characteristics of the actinomycotic infection, early diagnosis should be made especially in the oral cavity to prevent the hazardous spread of the disease. Hence, actino-

mycosis should be included in the differential diagnosis of neoplasms and chronic suppurative and granulomatous lesions of the maxillofacial region.

## References

- 1 Belmont MJ, Behar PM, Wax MK. Atypical presentation of actinomycosis. *Head Neck*. 1999; **21**: 264 – 268.
- 2 Palonta F, Preti G, Vione N, Cavalot AL. Actinomycosis of the masseter muscle: report of a case and review of the literature. *J Craniofac Surg*. 2003; **14**: 915 – 918.
- 3 Mendell GL. *Principles and Practice of Infectious Disease*. New York: Churchill Livingstone; 1992: 170.
- 4 Brignall ID, Gilhooly M. Actinomycosis of the tongue. A diagnostic dilemma. *Br J Oral Maxillofac Surg*. 1989; **27**: 249 – 253.
- 5 Atespare A, Keskin G, Ercin C, Keskin S, Camcioglu A. Actinomycosis of the tongue: a diagnostic dilemma. *J Laryngol Otol* 2006; **120**: 681 – 683.
- 6 Gerbino G, Bernardi M, Secco F, Sapino A, Pacchioni D. Actinomycosis of the tongue: report of two cases and review of the literature. *Minerva Stomatol*. 1998; **45**: 98 – 101.
- 7 van der Waal I, Pindborg JJ. *Diseases of the Tongue*. Chicago: Quintessence Publishing; 1986: 57 – 58.
- 8 Ficarra G, Di Lollo S, Pierleoni F, Panzoni E. Actinomycosis of the tongue: a diagnostic challenge. *Head Neck*. 1993; **15**: 53 – 55.
- 9 Benhoff DF. Actinomycosis: diagnostic and therapeutic consideration and a review of 32 cases. *Laryngoscope*. 1984; **94**: 1198 – 1217.
- 10 Happonen RP, Viander M. Comparison of fluorescent antibody technique and conventional staining methods in diagnosis of cervicofacial actinomycosis. *J Oral Pathol*. 1982; **11**: 417 – 425.
- 11 Sakallioğlu U, Acikgoz G, Kirtiloglu T, Karagoz F. Rare lesions of the oral cavity: case report of an actinomycotic lesion limited to the gingiva. *J Oral Sci*. 2003; **45**: 39 – 42.
- 12 Martin MV. Antibiotic treatment of cervicofacial actinomycosis for patients allergic to penicillin: a clinical and *in vitro* study. *Br J Oral Maxillofac Surg*. 1985; **23**: 428 – 434.
- 13 Shaheen SQ, Ellis FG. Actinomycosis of the larynx. *J R Soc Med*. 1983; **76**: 226 – 229.
- 14 Peterson LJ, Ellis IE, Hupp JR, Tucker MR. *Contemporary Oral and Maxillofacial Surgery*. 3rd ed. St. Louis: Mosby; 1998: 428 – 429.