

---

## Case Report

---

# Bilateral Invasive Ductal Carcinoma in a Woman with Neurofibromatosis Type 1

Mozhgan Alamsamimi MD\*, Nooshin Mirkheshti MD\*\*, Mohammad-Reza Mohajery MD\*\*\*, Mozhgan Abdollahi MD\*

---

**A 51-year-old woman with neurofibromatosis type 1 presented to our department for investigation of a left breast lump (50×50×30 mm); a mass in the right breast (40×40×20 mm) was also detected on physical examination. The lumps were suspected to be malignant based on physical examination and ultrasonography. Biopsy and frozen sections subsequently confirmed a diagnosis of bilateral invasive ductal carcinoma. A standard bilateral radical mastectomy was performed, followed by postoperative chemoendocrine therapy. Tumor recurrence has not been observed within the first 23 months following the surgery.**

*Archives of Iranian Medicine, Volume 12, Number 4, 2009: 412 – 414.*

---

**Keywords:** Breast cancer • invasive ductal carcinoma • neurofibromatosis

### Introduction

**N**eurofibromatosis type 1 (NF1) is an autosomal dominant disease characterized by cafe-au-lait spots, freckling in the axillary and inguinal regions, peripheral neurofibromas, and Lisch nodules.<sup>1-3</sup> The NF1 gene is a tumor-suppressor gene and those with the mutation are at the risk of cancer four times greater than general population.<sup>4-6</sup> Patients with NF1 have a greatly increased relative risk of developing gliomas, malignant peripheral nerve sheath tumors, juvenile chronic myelomonocytic leukemia, rhabdomyosarcoma, and pheochromocytoma. These tumors may have a different natural history from those occurring sporadically, and require a specific approach to their detection and management.<sup>7</sup>

Recently there are some reports on breast cancer in patients with NF1<sup>8-12</sup> and Sharif et al.

confirmed an increased risk of breast cancer in patients with NF1.<sup>7</sup> In this article, a 51-year-old woman with bilateral invasive ductal carcinoma and NF1 is presented. Review of the literature reveals that this is the first presentation of an NF1 patient with bilateral invasive ductal carcinoma.

### Case Report

A 51-year-old woman with NF1 presented with a persistent lump, getting larger gradually. Family history revealed that her sister had been also affected with breast cancer (lobular invasive ductal carcinoma) at the age of 47 years. A physical examination of the breast revealed a lump about 5 cm in the left breast and a well-defined mass about 5 cm in the right breast. Axillary lymphadenopathy was absent. The patient didn't agree to take some pictures from her breasts' lumps. On mammogram, a left breast lump in the inferolateral segment and a mass in the upper lateral site of the right breast were detected (Figure 1).

An ultrasonography demonstrated a left breast lump (50×50×30 mm) and a mass in the right breast (40×40×20 mm). The patient subsequently underwent a bilateral mastectomy and, further, both radioimmunoassay and dye-guided sentinel lymph node (SLN) biopsy. Because of positive findings on a frozen section of SLN, dissection of

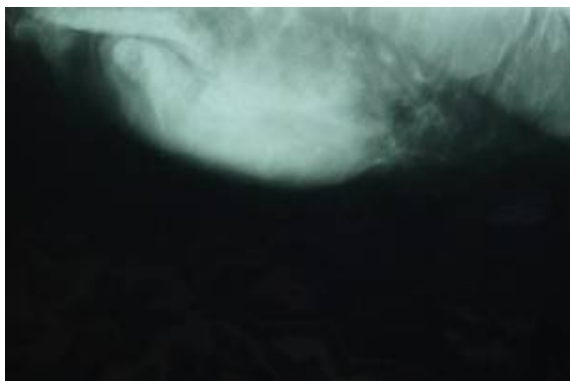---

**Authors' affiliations:** Department of Hematology, \*Seyed Al-shohada Hospital, Isfahan University of Medical Sciences, \*\*East Sage Investigative Corporation, Isfahan Science and Technology Town, \*\*\*Department of Pathology, Mohajeri Laboratory, Isfahan, Iran.

**Corresponding author and reprints:** Nooshin Mirkheshti MD, East Sage Investigative Corporation, Isfahan Science and Technology Town. No. 5, Ghezelbash St., Tohid Ave., Isfahan, Iran.

Tel: +98-311- 667-17-80, E-mail: nooshinmirkheshti@gmail.com

Accepted for publication: 30 October 2008



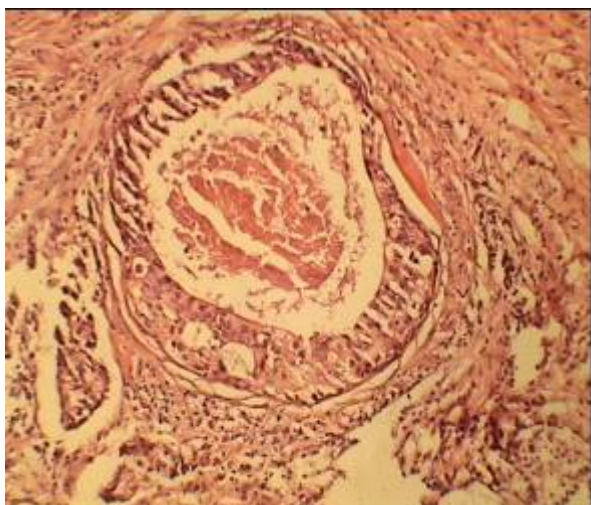
**Figure 1.** Standard mammogram of the right breast.

ipsilateral axillary lymph nodes was performed. The histopathologic diagnosis was invasive ductal carcinoma in both breasts (Figure 2).

On dissection of axillary lymph nodes, the SNL was negative for carcinoma. The carcinoma cells showed positive immunohistochemical reaction for estrogen and progesterone receptors. Amplification of c-erb-B2 (HER2/neu) was proven by fluorescence *in situ* hybridization. Postoperatively, the patient was treated with TAC chemotherapy regimen including taxotere, adriamycine, and cyclophosphamide, four times. Radiation therapy was (XRT) performed and now she is on tamoxifen. Tumor recurrence has not been observed during 23 months after the surgery.

## Discussion

NF1 is an autosomal dominant disease with high penetrance but wide variability in expression. The NF1 gene is located in the pericentromeric region of the long arm of chromosome 17. The



**Figure 2.** Histologic examination of the surgical specimen of the right breast tumor shows ductal carcinoma with central necrosis (H&E ×20).

extremely large size of the gene is consistent with the high spontaneous mutation rate of neurofibromatosis.<sup>11</sup> The NF1 gene encodes a protein-designated neurofibromin, which functions as a tumor suppressor gene.<sup>2</sup> It also accelerates the inactivation of RAS oncogene; in addition neurofibromin was reported as nearly absent in the human breast cancer-MDA-MP-231 cell line.<sup>13</sup>

It should be mentioned that both breast cancer 1, early onset (BRCA1) and NF1 are located on the long arm of chromosome 17.<sup>14</sup> Regarding this, it is probable that the mutation in NF1 gene is associated with some mutations in BRCA1 gene. According to this information studying the BRCA1 mutation in patients with NF1 may present more beneficial data in this field. In addition, in NF1 patients, detection of breast cancer may be delayed because the presence of numerous NF skin tumors hinders the detection of breast lumps.<sup>15</sup> As the incidence of breast cancer is increasing, it stands to reason that its simultaneous occurrence with NF1 will increase correspondingly. Early evaluation and treatment are recommended when any suspicious clinical data are found in NF1 patients.

## References

- 1 Silverman N, Kuhn JP. Brain and spinal cord. In: Silverman FN, Kuhn JP, eds. *Caffey's Pediatric X-Ray Diagnosis: An Integrated Imaging Approach*. St Louis: Mosby Inc; 1993: 1420 – 1421.
- 2 Jone KL. *Smith's Recognizable Patterns of Human Malformation*. Philadelphia: WB Saunders; 1988: 452.
- 3 Husan MS, Korf BR. The Phakomatoses. In: Rimoin DL, Connor JM, Pyeritz RE, Korf RB, eds. *Emery and Rimoin's Principle and Practice of Medical Genetics*. New York: Churchill- Livingstone; 2002: 3162 – 3203.
- 4 Airewele GE, Sigurdson AJ, Wiley KJ, Frieden BE, Calderera LW, Riccardi VM, et al. Neoplasms in neurofibromatosis 1 are related to gender but not to family history of cancer. *Genet Epidemiol*. 2001; **20**: 75 – 86.
- 5 Sorensen SA, Mulvihill JJ, Nielsen A. Long-term follow-up of von Recklinghausen neurofibromatosis. Survival and malignant neoplasms. *N Engl J Med*. 1986; **314**: 1010 – 1015.
- 6 Zoller ME, Rembeck B, Oden A, Samuelsson M, Angervall L. Malignant and benign tumors in patients with neurofibromatosis type 1 in a defined Swedish population. *Cancer*. 1997; **79**: 2125.
- 7 Sharif S, Moran A, Huson SM, Iddenden R, Shenton A, Howard E, et al. Women with neurofibromatosis 1 are at a moderately increased risk of developing breast cancer and should be considered for early screening. *J Med Genet*. 2007; **44**: 481 – 484.
- 8 Natsiopoulou I, Chatzichristou A, Stratis I, Skordalaki A, Makrantonakis N. Metaplastic breast carcinoma in a patient with von Recklinghausen's disease. *Clin Breast Cancer*. 2007; **7**: 573 – 575.

- 9 Kawawa Y, Okamoto Y, Oharaseki T, Takahashi K, Kohda E. Paget's disease of the breast in a woman with neurofibromatosis. *Clin Imaging*. 2007; **31**: 127 – 130.
- 10 Posada JG, Chakmakjian CG. Images in clinical medicine. von Recklinghausen's disease and breast cancer. *N Engl J Med*. 2005; **352**: 1799.
- 11 Güran S, Safali M. A case of neurofibromatosis and breast cancer: loss of heterozygosity of NF1 in breast cancer. *Cancer Genet Cytogenet*. 2005; **156**: 86 – 88.
- 12 Nakamura M, Tangoku A, Kusanagi H, Oka M, Suzuki T. Breast cancer associated with von Recklinghausen's disease: report of a case. *Nippon Geka Hokan*. 1998; **67**: 3 – 9.
- 13 Ogata H, Sato H, Takatsuka J, De Luca LM. Human breast cancer MDA-MB-231 cells fail to express the neurofibromin protein, lack its type I mRNA isoform, and show accumulation of P-MAPK and activated RAS. *Cancer Lett*. 2001; **172**: 159 – 164.
- 14 Ceccaroni M, Genuardi M, Legge F, Lucci-Cordisco E, Carrara S, D'Amico F, et al. BRCA1-related malignancies in a family presenting with von Recklinghausen's disease. *Gynecol Oncol*. 2002; **86**: 375 – 378.
- 15 Nakamura M, Tangoku A, Kusanagi H, Oka M, Suzuki T. Breast cancer associated with Recklinghausen's disease: report of a case. *Nippon Geka Hokan*. 1998; **67**: 3 – 9.