

Original Article

Immunophenotypic Pattern and Cytokine Profiles of Dry Type Cutaneous Leishmaniasis

Simin Meymandi MD^{*}, Shahriar Dabiri MD^{**}, Manzumeh Shamsi-Meymandi MSc^{***}, Hossein Nikpour MD^{**}, Arsalan Kharazmi PhD[†]

Background: Dry type localized cutaneous leishmaniasis, one of the most prevalent cutaneous parasitic infections in Kerman Province, is presented as a polarized disease in which cytokine profiles secreted by immune cells play a major role in its presentation. In order to clarify the idea, immunohistochemical study of skin biopsies were performed to elucidate the cytokine release capabilities of immune cells.

Methods: Skin biopsies of acute, chronic nonlupoid, and chronic lupoid recidivans lesions of dry type localized cutaneous leishmaniasis were studied by immunohistochemical staining methods for immunophenotypic patterns (CD4, CD8, CD14, CD19, CD56, CD11a, CD18, CD1a, HLA-DR, CD54) and cytokines (INF-gamma, IL-12, IL-4, TNF-alpha) released by immune inflammatory cells.

Results: The descriptive analysis of data showed that the mean percentage of positive immunostained cells of CD4, CD8, and CD14; antigen-presenting cells (CD1a, HLA-DR); and markers of the extravasated positive memory T cells (CD11a, CD18, CD54) are more frequent in lupoid recidivans than in acute active and chronic nonlupoid lesions, in order of frequency.

Conclusion: Based on the results, it seems that Th1-like response is predominant in acute active form and lupoid recidivans while Th2-like response is predominant in chronic nonlupoid lesions. It seems that lupoid recidivans is a type IV hypersensitivity reaction to the reactivation of hidden antigens.

Archives of Iranian Medicine, Volume 12, Number 4, July 2009: 371 – 376.

Keywords: Cutaneous leishmaniasis • cytokines • immunophenotyping • Th1 cells • Th2 cells

Introduction

Human leishmaniasis presented a wide range of spectrum, from a self-healing localized cutaneous to a fatal systemic visceral form. A large number of sophisticated studies have been performed to evaluate the histogenesis and probable underlying immunopathogenic basis of various types of the disease. Previous studies on murine model of *Leishmania*

major leishmaniasis revealed the cross-activation and inactivation of a subset of CD4+ T cells either Th1 or Th2 cells involved in disease resolution and/or progression. Th1 cells are usually capable to produce a large amount of Interleukin-2 (IL-2) and interferon-gamma (INF-gamma) which are critical for macrophage activation resulting in intracellular killing of parasites. On the other hand, Th2 cells produce IL-4 and IL-5, which are mostly involved in B cell maturation and differentiation to produce antibodies that are not directly participated in parasite resolution.^{1,2} Dry type localized cutaneous leishmaniasis (DLCL) is the second most frequent parasitic infection in Kerman Province, an area close to the central desert of Iran.^{3,4}

Clinical presentation and histopathologic classifications of DLCL differ from the other types of the disease. DLCL is clinically presented within a wide spectrum of acute and chronic (chronic

Authors' affiliations: *Department of Dermatology, **Department of Pathology, ***Department of Pharmacology, Kerman Medical School, Kerman Leishmaniasis Research Center, Kerman, Iran, †Department of Microbiology and Immunology, Copenhagen Medical School; Copenhagen, Denmark.

Corresponding author and reprints: Simin Meymandi MD, Department of Dermatology, Afzalipour Medical School, Kerman University of Medical Sciences, P.O. Box: 444, Kerman, Iran.

Tel: +98-341-2451034, Fax: +98-341-2442100

E-mail: meymandi_s@hotmail.com

Accepted for publication: 15 April 2009

nonlupoid and chronic lupoid) forms. Chronic lupoid is more frequent in the exposed regions mostly in face.⁵ However, the immunophenotypic patterns of different inflammatory-immune cells and cytokine profiles released by these cells in DLCL have not been thoroughly investigated. It seems that chronic non-lupoid lesions are probably infiltrated by mononuclear cells which are capable of producing Th2 cytokines, whereas acute and lupoid recidivans lesions would be dominated by Th1 cells. In order to elucidate this idea, immunohistochemical study of skin biopsies was performed in Iranian patients with DLCL.

Patients and Methods

After getting medical consents from the patients who were referred to Kerman hospitals and/or private clinics, six patients with nontreated lesions (two in hands, two in face, one in elbow, and one in ankle) with less than two years were classified as acute lesion (group I). Three cases (two in hands and one in foot) with nonhealed, more than two years duration were classified as chronic nonlupoid lesions (group II); none of them had responded successfully to routine therapies. Three cases (two in face and one in foot) with multiple cherry red papules circled the old healed scars were classified as lupoid recidivans (group III).

Considering research ethics, the past history and the present clinical data were recorded in a data sheet and skin biopsies were performed under a mild local anesthesia. The tissue sections were divided into two parts, one was fixed in 10% neutral formalin and the other part was frozen in liquid nitrogen. The frozen sections processed for immunoperoxidase staining using a gallery of monoclonal antibodies which have been stained at Copenhagen Medical School. Immunoperoxidase stainings were: CD4 (Dako M0716, dilution factor[df]; 1:10), CD8 (Dako M0707, df; 1:100), CD1a (Dako M0721, df; 1:100), CD14 (M0852, df; 1:10), HLA-DR (Dako M0704, df; 1:50), CD19 (Dako M0740, df; 1:25), CD56 (Dako M0852, df; 1:10), CD11a (Dako M0782, df; 1:50), CD18 (Dako M0783, df; 1:50), CD54 (Dako M7063, df; 1:20), INF-gamma (Genzyme, 1598-00, df; 1:20), IL-12 (R&D, MAB219, df; 1:25), IL-4 (Genzyme, 1842 -01, df; 1:10), and TNF-alpha (R&D, MAB219, df; 1:25). Negative control mouse IgG 1 (Dako, X0931, df; 1:10) run in parallel to evaluate the tests' results. The procedure was based on

concomitant protocol of staining.⁶ To reduce internal errors, four experienced pathologists blindly observed the two stained specimens independently, and scoring of the slides performed under a uniform protocol. The percentage of the cells stained immunohistochemically determined among 200 – 400 cell populations in 0.0009 mm² areas with high-power field ($\times 40$).

The descriptive analysis was based on three phases of pathogenesis: first, presentation of antigens by antigen-presenting cells (APC as CD1a, HLA-DR) and adhesion molecules which help the extravasation of positive memory T cells into inoculated site (CD11a, CD18, and CD54); second, gathering of immune cells in the lesion (CD4, CD8, CD14, CD19, and CD56); and finally the release of cytokines by memory T cells as Th1 versus Th2 responses at inflamed skin in subsequent groups. Th1 response was calculated by mean of the summation of positive cells of INF-gamma, TNF-alpha, and IL-12, and Th2 response as mean of positive cells of IL-4. The data were expressed in mean \pm SE in descriptive analysis calculated by SPSS Software Version 13.

Results

Immunostaining findings revealed the mean percentage of CD1a-positive cells, HLA-DR, CD11a, CD18, and CD54 in groups I, II, and III. CD1a-positive cells in group III were increased compared to other groups. Those chemokine-specific receptors on T cells and endothelial cells; CD11a, CD18, and CD54 which present recruitment of memory and effectors T lymphocytes after passing the dermal vessels were more prominent in groups I and III rather than in group II (Figure 1).

The immunostained assessment of the mean percentage of CD4, CD8, and CD14-positive cells in groups I, II, and III is shown in Figure 2, respectively. CD4 (24.6 \pm 2.5), CD8 (10.5 \pm 1.3), and CD14 (33.3 \pm 3.8)-positive cells had the highest values in group III compared to groups I and II. CD56 which represents natural-killer cells and CD19 which represents B lymphocytes were rarely seen in all groups (Figure 2). The mean percentage of positive immune cells' releasing-cytokines were: 6.4 \pm 0.7, 16.0 \pm 3.5, and 3.2 \pm 1.1 for IL-4; 10.4 \pm 0.7, 8.5 \pm 1.0, and 14.1 \pm 5.2 for IL-12; 9.1 \pm 1.4, 13.6 \pm 5.4, and 8.7 \pm 3.6 for TNF-alpha; and 14.3 \pm 1.6, 6.4 \pm 1.6, and 14.1 \pm 5.2 for INF-gamma in

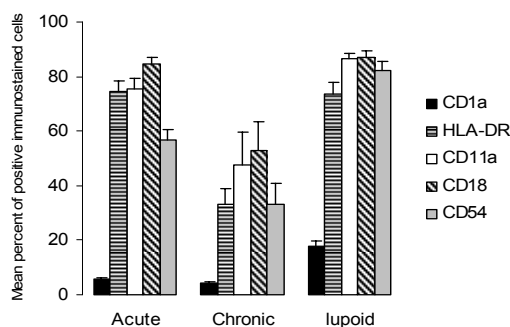


Figure 1. The mean percentage of positive immunostained antigen-presenting cells; CD1a, HLA-DR, CD11a, CD18, and CD54 of acute, chronic, and lupoid recidivans lesions. CD1a is prominent in lupoid recidivans. Other parameters are decreased in chronic nonhealed lesions.

groups I, II, and III, respectively (Figure 3). Finally, Th1-like response (as the summation of positive cells of INF-gamma, TNF-alpha, IL-12) and Th2 responses (as the mean of positive cells of IL-4) were shown in Figure 4. A probable imbalance between Th1 and Th2 responses was noticed in group III compared to other groups (Figure 4).

Discussion

It has been proved both in murine and human leishmaniasis that cell mediated immunity plays a major role in protection against the infection. Susceptible strain of mice infected with *Leishmania major* present the disease as a disseminated, lethal leishmaniasis. Peripheral

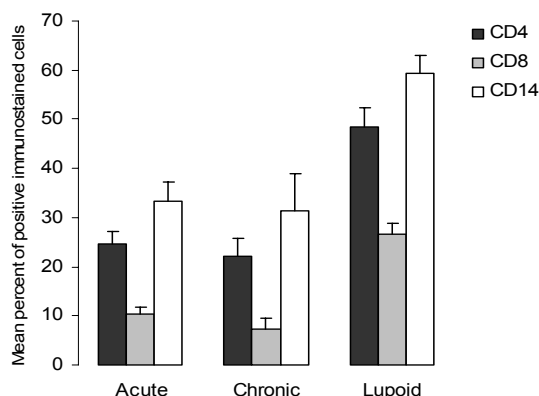


Figure 2. The mean percentage of positive immunostained cells of immune cells in lesions; CD4, CD8, and CD14 of acute, chronic (nonhealed), and lupoid recidivans. In lupoid recidivans all above parameters are markedly prominent. CD56 and CD19 are rarely observed.

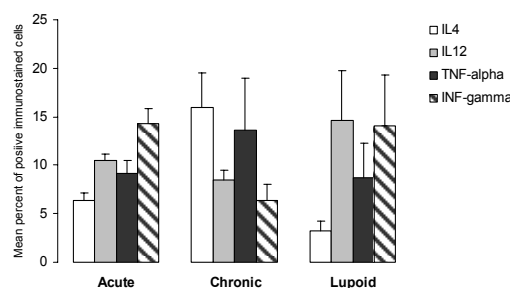


Figure 3. The mean percentage of positive immune cells releasing-cytokine of IL-4, IL-12, TNF-alpha, and INF-gamma in acute, chronic (nonhealed), and lupoid recidivans groups.

mononuclear cells of these animals cultivated *in vitro* secreted predominantly Th2 cytokines including IL-4, IL-5, and IL-6, while in culture of mononuclear cells of resistant strains of infected mice INF-gamma, IL-2, and TNF-alpha were markedly characterized.⁷ According to our findings in groups I and III, more picked-up antigens by APCs might be exposed to skin-draining lymph nodes and profound influx and extravasations of the memory immune cells occur at the inoculated sites⁹ which resulted in Th1 response predominance. In contrast, in group II, decreased antigen-presenting cells (APCs) and extravasated memory immune cells at the inflamed site, resulted in predominance of Th2 response and chronicity of the disease. Robert and Kupper in an excellent review article of immunogenicity of inflammatory skin diseases mentioned that APCs, such as Langerhans and dermal dendritic cells, that resided in the skin, internalized foreign antigens in the skin and migrated to the lymph nodes through afferent lymphatics.⁸ When a naive T cell encountered the

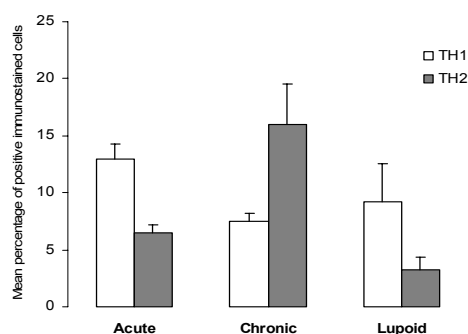


Figure 4. The mean percentage of positive immunostained cells of acute, chronic (nonhealed), and lupoid recidivans lesions based on Th1-like cells secreting INF-gamma, TNF-alpha and IL-12, and Th2-like cells secreting IL-4. In acute and lupoid recidivans lesions Th1 and in chronic Th2 response is dominant, respectively.

specific antigen on an APC in a skin-draining lymph node, it was activated and became a memory T cell, with the expression of cutaneous lymphocyte antigen (CLA) and a distinct set of chemokine receptors. Therefore, skin injury or infection resulted in the activation of the nuclear factor-kB (NF-kB) pathway through cytokine receptors (i.e., TNF-alpha).

To extravasate into the skin, a memory T cell must be trapped in luminal postcapillary venules. The binding of the chemokines to specific receptors on T cells resulted in a modification of the structure of the integrins (lymphocyte function-associated antigen-1 LFA-1); so, they could bind to intercellular adhesion molecule-1 (ICAM-1), and vascular cell adhesion molecule-1 (VCAM-1), respectively. Not only the integrin binding had a high affinity to arrest the CLA-positive T cells, but also it favored the flattening of the lymphocytes in preparation for their extravasations through the endothelial layer. Once extravasated on the abluminal side of the vessel, the T cells were no longer subjected to shear forces from blood flow and they could respond to chemotactic gradients emanating from the site of injury or infection. If these T cells encounter antigens in tissues, they would become activated. The subsequent release of T-cell cytokines would modify and expand the inflammatory infiltration.⁸ el Hassan et al. showed these APC translocations from the epidermis to the dermis, where they took up antigens and migrated to the paracortex, could be involved in the generation of *Leishmania*-specific T memory cells.⁹ LFA-1-positive T cells of the CD45RO phenotype were found in the skin lesions. Venular endothelium in the skin lesions expressed ICAM-1, which was the ligand for LFA-1.

The migration of the lymphocytes from the vascular lumen to the site of inflammation is possibly a result of the interaction between these two adhesion molecules.⁹ Costa et al. suggested that early activation events occurring in the lymph nodes of recently infected patients with *Leishmania* lead to changes in T cell adhesion molecule expression which favor migration to the periphery and increase in the likelihood of further recruitment to lesion site.¹⁰ Moll et al., proposed in murine leishmaniasis that Langerhans cells took up parasites in the skin and transported them to the draining lymph node for presentation to T cells and initiation of the specific immune response.¹¹ The number of Langerhans cells were higher in early lesions of resistant C57BL/6 mice.¹² On the other

hand, Azadeh et al. mentioned that *Leishmania tropica* antigen staining was positive in *Leishmania amastigote*, granuloma, and vascular smooth muscle cells of lymph nodes in localized *Leishmania* lymphadenitis.¹³ We also noticed that macrophages and Langerhans cells were harboring Leishman bodies in lymph nodes of the localized *Leishmania* lymphadenitis in self-healing varieties of leishmaniasis; it seems that better presentation of antigens to immune cells triggers a synergistic effect of immune cells on activity of macrophages to eradicate engulfed intracellular parasites.¹⁴ Immunostaining findings in localized cutaneous leishmaniasis (LCL) due to *Leishmania braziliensis guyanensis* showed more expression of IL-2 in T cells while HLA-DR+ and helper cells exceeded those CD+ 8 T-cell subsets. Slight increased of CD1a (Langerhans cells) were noticed as well.¹⁵ Gaafar et al. showed that high production of INF-gamma without IL-4 production (a Th1-like pattern) in mild form and low INF-gamma with IL-4 production (not a Th1-like pattern) were seen in severe LCL due to *Leishmania major*.¹⁶ In another immunohistochemical study, the authors mentioned that the cytokine pattern in peripheral mononuclear cells in response to *Leishmania* antigen was more specific than in the lesion and correlated better with clinical manifestations.¹⁷ Our findings were more in favor of Ajdary et al. who showed in peripheral blood mononuclear cells a Th1-like response in active lesion and a Th2-like response in nonhealed lesion of LCL induced by *Leishmania major*.¹⁸ Alimohammadian et al. showed that exposure to *Leishmania major* modulates the proportion of CD4 T lymphocytes without affecting cellular immune response and the production of INF-gamma was increased in exposed individuals.¹⁹ Diaz et al. mentioned that INF-gamma production was contributing to the resolution of the lesion during the course of *Leishmania mexicana* infection in resistant C57BL/6 mice.¹² Recruitment of the memory T cells in our series of the increased percentage of positive IL-4 cells in nonhealed chronic lupoid lesion may be correlated with findings of inhibitory effect of this cytokine on Th1 activities and Th2 cell induction.²⁰⁻²² The susceptible BALB/C mice developed chronic and progressive lesions with predominance of IL-4, Th2 cells.

We have the hypothesis that UV light may damage dermal fibroblasts which might have hidden the *Leishmania* antigen within them. Langerhans cells carried the antigen to the regional

lymph nodes and presented and expressed them to the memory T cells and caused influx of these memory cells to the damaged areas and initiating or triggering delayed type (IV) hypersensitivity reaction. In support of this hypothesis, reviewing of the literature reveals that PCR studies confirmed the presence of *Leishmania* DNA molecule in granulomatous tissue of chronic lupoid leishmaniasis.⁵ Bogdan et al. showed 40% of persistent parasites within a fibroblastic meshwork of the draining lymph node using confocal microscopy in healed murine leishmaniasis. They suggested that fibroblast could be a safe target for parasites in clinically latent disease.²³ Similar intracytoplasmic Leishman bodies within the fibroblasts were cytologically noticed.²⁴ UV irradiation of human dermal fibroblasts induced interstitial collagenase and stromelysin via the synthesis and release of IL-6²⁵; furthermore, UV irradiation in HIV-infected individuals also induced transcription and expressions of the virus through activation of cellular NF- κ B.²⁶ We suggested that lupoid recidivans could be reactivation of active lesions. The unanswered question still is that some stimulators trigger which one: new antigens or reactivation of hidden antigens?

Acknowledgment

The authors would like to thank Mirshekar MD, A. Abdirad MD, K. Kemp PhD, T.G. Theandar PhD, H. Permin MD, and Mrs. Lis Christensen for excellent immunostaining of frozen specimen. This research is funded by a grant of Danish International Development Assistance (DANIDA) and support of Clinical Microbiology Department, Copenhagen Medical School, Denmark.

References

- 1 Kharazmi A, Kemp K, Ismail A, Gasim S, Gaafar A, Kurtzhals JA, et al. T-cell response in human leishmaniasis. *Immunol Lett.* 1999; **65**: 105 – 108.
- 2 Pirmez C, Yamamura M, Uyemura K, Paes-Oliveira M, Conceicao-Silva F, Modlin RL. Cytokine patterns in the pathogenesis of human leishmaniasis. *J Clin Invest.* 1993; **91**: 1390 – 1395.
- 3 Ardehali S, Moattari A, Hatam GR, Hosseini SM, Sharifi I. Characterization of *Leishmania* isolated in Iran: 1. Serotyping with species specific monoclonal antibodies. *Acta Trop.* 2000; **75**: 301 – 307.
- 4 Sharifi I, Fekri AR, Aflatonian MR, Nadim A, Nikian Y, Kamesipour A. Cutaneous leishmaniasis in primary school children in the south-eastern Iranian city of Bam, 1994 – 1995. *Bull World Health Organ.* 1998; **76**: 289 – 293.
- 5 Momeni AZ, Yotsumoto S, Mehregan DR, Mehregan AH, Mehregan DA, Aminjavaheri M, et al. Chronic lupoid leishmaniasis. Evaluation by polymerase chain reaction. *Arch Dermatol.* 1996; **132**: 198 – 202.
- 6 Ismail A, AM, Kemp K, Gasim S, Kadaru AE, Moller T, et al. Immunopathology of post kala-azar dermal leishmaniasis (PKDL): T-cell phenotypes and cytokine profile. *J Pathol.* 1999; **189**: 615 – 622.
- 7 Kemp M, Theander TG, Kharazmi A. The contrasting roles of CD4+ T cells in intracellular infections in humans: leishmaniasis as an example. *Immunol Today.* 1996; **17**: 13 – 16.
- 8 Robert C, Kupper TS. Inflammatory skin diseases, T cells, and immune surveillance. *N Engl J Med.* 1999; **341**: 1817 – 1828.
- 9 el Hassan AM, Gaafar A, Theander TG. Antigen-presenting cells in human cutaneous leishmaniasis due to *Leishmania major*. *Clin Exp Immunol.* 1995; **99**: 445 – 453.
- 10 Costa RP, Gollob KJ, Machado PR, Bacellar OA, Almeida RP, Barral A, et al. Adhesion molecule expression patterns indicate activation and recruitment of CD4+ T cells from the lymph node to the peripheral blood of early cutaneous leishmaniasis patients. *Immunol Lett.* 2003; **90**: 155 – 159.
- 11 Moll H, Flohe S, Rollinghoff M. Dendritic cells in *Leishmania major*-immune mice harbor persistent parasites and mediate an antigen-specific T-cell immune response. *Eur J Immunol.* 1995; **25**: 693 – 699.
- 12 Diaz NL, Fernandez M, Figueira E, Ramirez R, Monsalve IB, Tapia FJ. Nitric oxide and cellular immunity in experimental cutaneous leishmaniasis. *Clin Exp Dermatol.* 2003; **28**: 288 – 293.
- 13 Azadeh B, Sells PG, Ejeckam GC, Rampling D. Localized *Leishmania lymphadenitis*. Immunohistochemical studies. *Am J Clin Pathol.* 1994; **102**: 11 – 15.
- 14 Dabiri S, Meymandi SS, Nadji M, Kharazmi A. A description of parasite-harboring cells in localized lymphadenitis in dry type cutaneous leishmaniasis. *Acta Trop.* 2001; **79**: 129 – 133.
- 15 Esterre P, Dedet JP, Frenay C, Chevallier M, Grimaud JA. Cell populations in the lesion of human cutaneous leishmaniasis: a light microscopical, immunohistochemical, and ultrastructural study. *Virchows Arch A Pathol Anat Histopathol.* 1992; **421**: 239 – 247.
- 16 Gaafar A, Kharazmi A, Ismail A, Kemp M, Hey A, Christensen CB, et al. Dichotomy of the T- cell response to *Leishmania* antigens in patients suffering from cutaneous leishmaniasis: absence or scarcity of Th1 activity is associated with severe infections. *Clin Exp Immunol.* 1995; **100**: 239 – 245.
- 17 Gaafar A, Veress B, Permin H, Kharazmi A, Theander TG, el Hassan AM. Characterization of the local and systemic immune responses in patients with cutaneous leishmaniasis due to *Leishmania major*. *Clin Immunol.* 1999; **91**: 314 – 320.
- 18 Ajdary S, Alimohammadian MH, Eslami MB, Kemp K, Kharazmi A. Comparison of the immune profile of nonhealing cutaneous leishmaniasis patients with those with active lesions and those who have recovered from infection. *Infect Immun.* 2000; **68**: 1760 – 1764.
- 19 Alimohammadian MH, Darabi H, Malekzadeh S,

- Mahmoodzadeh-Niknam H, Ajdary S, Khamesipour A, et al. Exposure to *Leishmania major* modulates the proportion of CD4+ T-cells without affecting cellular immune responses. *Microbiol Immunol.* 2007; **51**: 1003 – 1011.
- 20 Launois P, Swihart KG, Milon G, Louis JA. Early production of IL-4 in susceptible mice infected with *Leishmania major* rapidly induces IL-12 unresponsiveness. *J Immunol.* 1997; **158**: 3317 – 3324.
- 21 Karp CL, el-Safi SH, Wynn TA, Satti MM, Kordofani AM, Hashim FA, et al. *In vivo* cytokine profiles in patients with kala-azar. Marked elevation of both interleukin-10 and interferon-gamma. *J Clin Invest.* 1993; **91**: 1644 – 1648.
- 22 Chatelain R, Varkila K, Coffman RL. IL-4 induces a Th2 response in *Leishmania major*-infected mice. *J Immunol.* 1992; **148**: 1182 – 1187.
- 23 Bogdan C, Donhauser N, Doring R, Rollinghoff M, Diefenbach A, Rittig MG. Fibroblasts as host cells in latent leishmaniasis. *J Exp Med.* 2000; **191**: 2121 – 2130.
- 24 Dabiri S, Hayes MM, Meymandi SS, Basiri M, Soleimani F, Mousavi MR. Cytologic features of "dry-type" cutaneous leishmaniasis. *Diagn Cytopathol.* 1998; **19**: 182 – 185.
- 25 Brenneisen P, Wlaschek M, Wenk J, Blandschun R, Hinrichs R, Dissemond J, et al. Ultraviolet-B induction of interstitial collagenase and stromelysin-1 occurs in human dermal fibroblasts via an autocrine interleukin-6-dependent loop. *FEBS Lett.* 1999; **449**: 36 – 40.
- 26 Vicenzi E, Poli G. Ultraviolet irradiation and cytokines as regulators of HIV latency and expression. *Chem Biol Interact.* 1994; **91**: 101 – 109.